

The Integumentary System: Skin

Integumentary vs Cardiovascular

- The skin is considered by most anatomists to be the largest organ of the body.
- Cardiovascular scientists, though, argue that the cardiovascular system with its system of vessels is the largest.
- Until there is an agreement between the two factions, we'll consider that the skin is the largest organ of the body.

Integumentary: Function

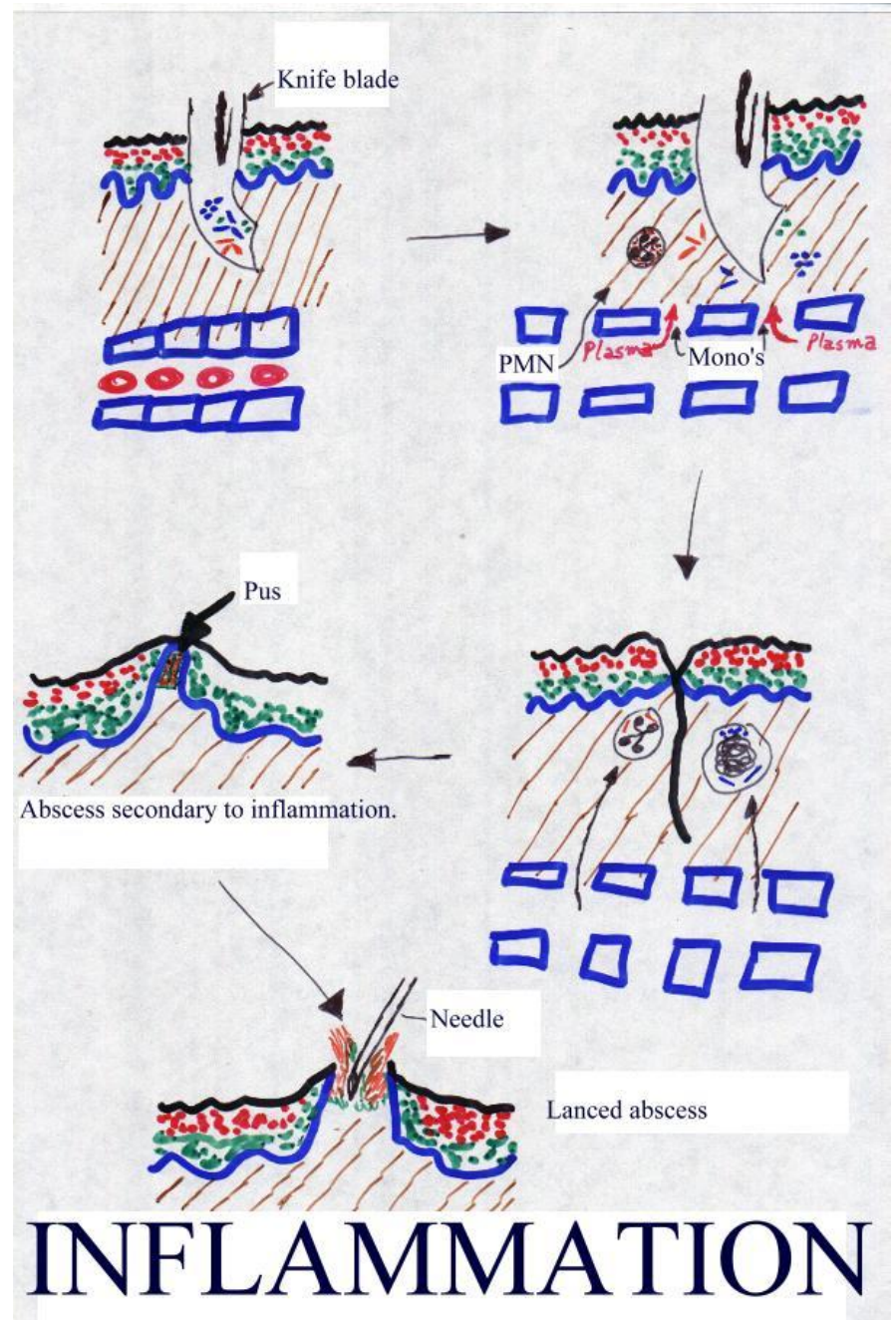
- The skin provides numerous functions to help protect the body.
- It regulates body temperature.
 - When our body temperature elevates or when we exercise, the skin increases sweat production, which leads to cooling via evaporation.
 - By altering changes in blood flow through the skin, the insulative properties are altered and effect temperature changes, as well.

Integumentary -- Function

- The skin is a physical barrier to the environment.
 - It protects us from physical abrasion.
- It helps fight off bacteria with specialized immune cells (Granstein cells and cells of Langerhans {macrophage-like cells from bone that migrate to the epidermis}) that interact with T cells.

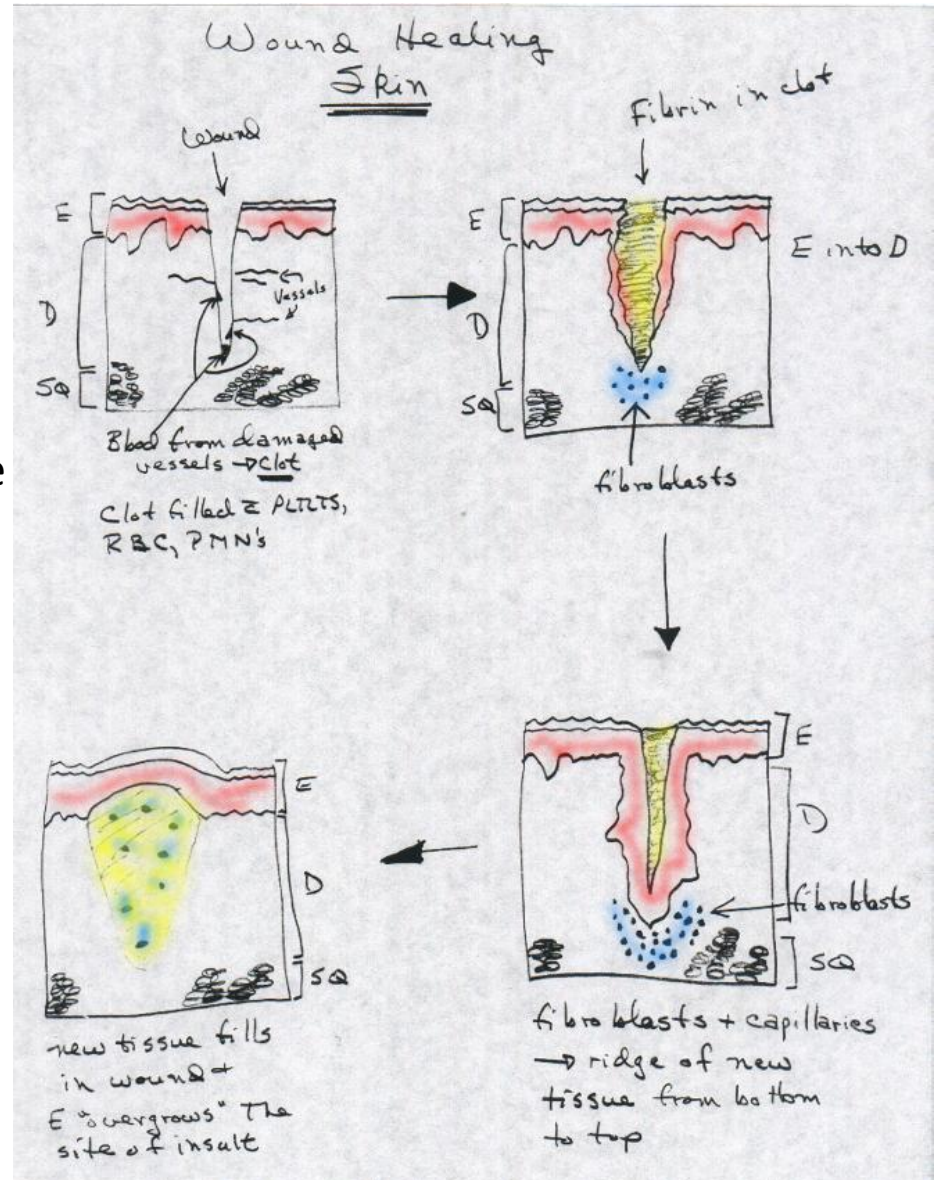
Inflammation

1. Somehow the skin barrier is violated (first cartoon, upper left).
2. When the skin is violated, bacteria, viruses, fungi are introduced into the wound (upper left and upper right of figure).
3. This causes Granstein cells and cells of Langerhans to work with white blood cells (PMN's and monocytes) that leak into the wound area with blood plasma.
4. The PMN's and monocytes phagocytize the invading organisms (middle right cartoon) and kill them.
5. Waste products from the phagocytic process accumulate beneath the healing wound causing an abscess (middle left cartoon) to form that is filled with pus.
6. Once lanced (bottom cartoon) and on antibiotics, if necessary, the abscessed wound heals.



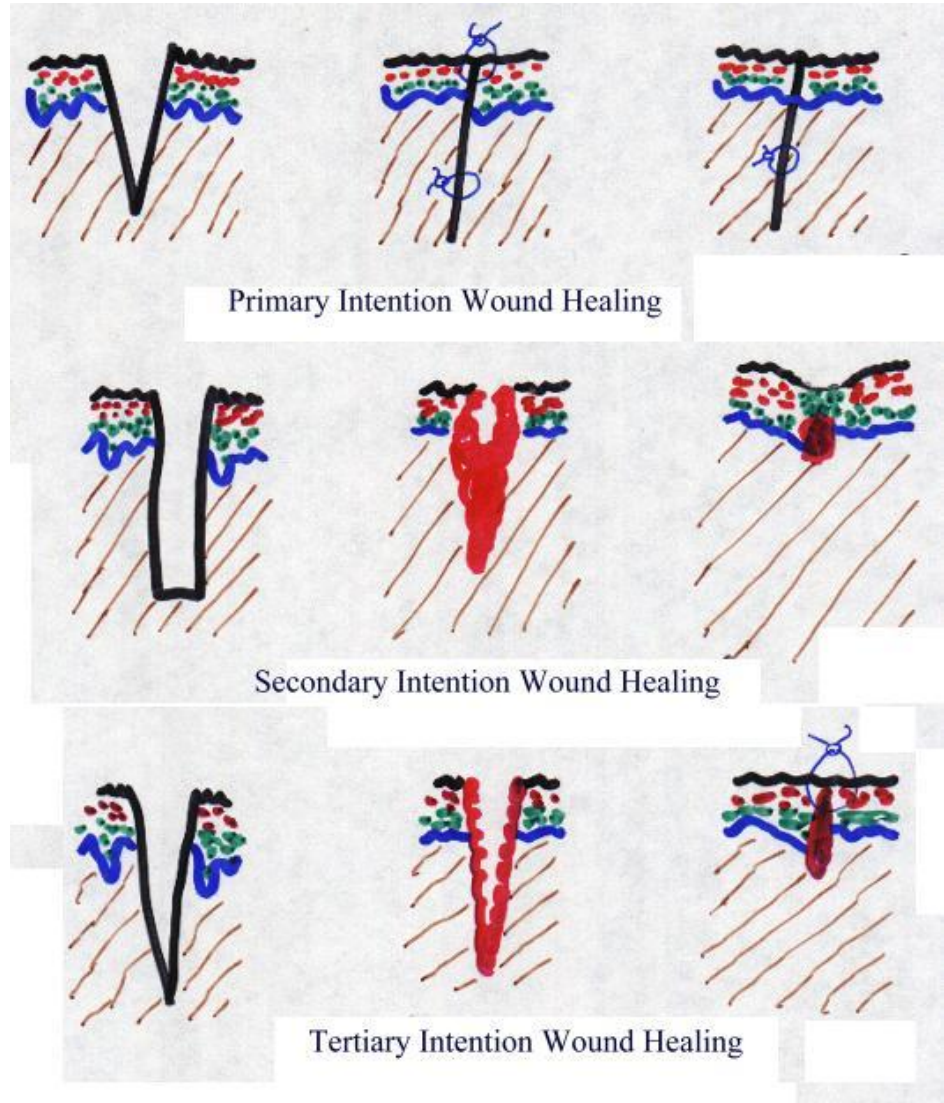
Wound Healing of An Inconsequential Nature

1. Starting from the upper left cartoon, note that blood from damaged vessels rushes into the wound to form a clot.
2. The clot is filled with platelets, red blood cells (RBC) and PMN's.
3. As the wound begins to further heal (upper right cartoon), note three phenomena: 1) there is fibrin in the clot, now, reinforcing the clot; 2) the epidermis is growing DOWN beneath the wound; 3) fibroblasts are migrating toward the wound.
4. In the bottom right cartoon, the wound is completely undergrown by the epidermis.
5. The fibroblasts working with the capillaries are forming a ridge of new tissue from BOTTOM TO TOP.
6. In the last cartoon, new tissue fills in the wound and the epidermis overgrows the site of insult.



Wound Healing Occurs by "Intention"

- Primary (or first degree),
 - First degree healing usually occurs after minimal injury, e.g., incision, edge-to-edge annealing, and leaves marginal scarring.
- Secondary (or second degree) or
 - Second degree healing usually follows a large injury. The repair of this wound is NOT simple. Obvious scarring with a red granular surface results.
- Tertiary (or third degree) intention wound healing
 - Third degree healing generally occurs in an area that has been previously sutured and it breaks down. This requires reclosure. Scar forms in a manner about half way between that of first and second degree intention wound healing.
- **BTW: the slim blue lines in the top and bottom cartoons represent sutures.**



Integumentary: Function

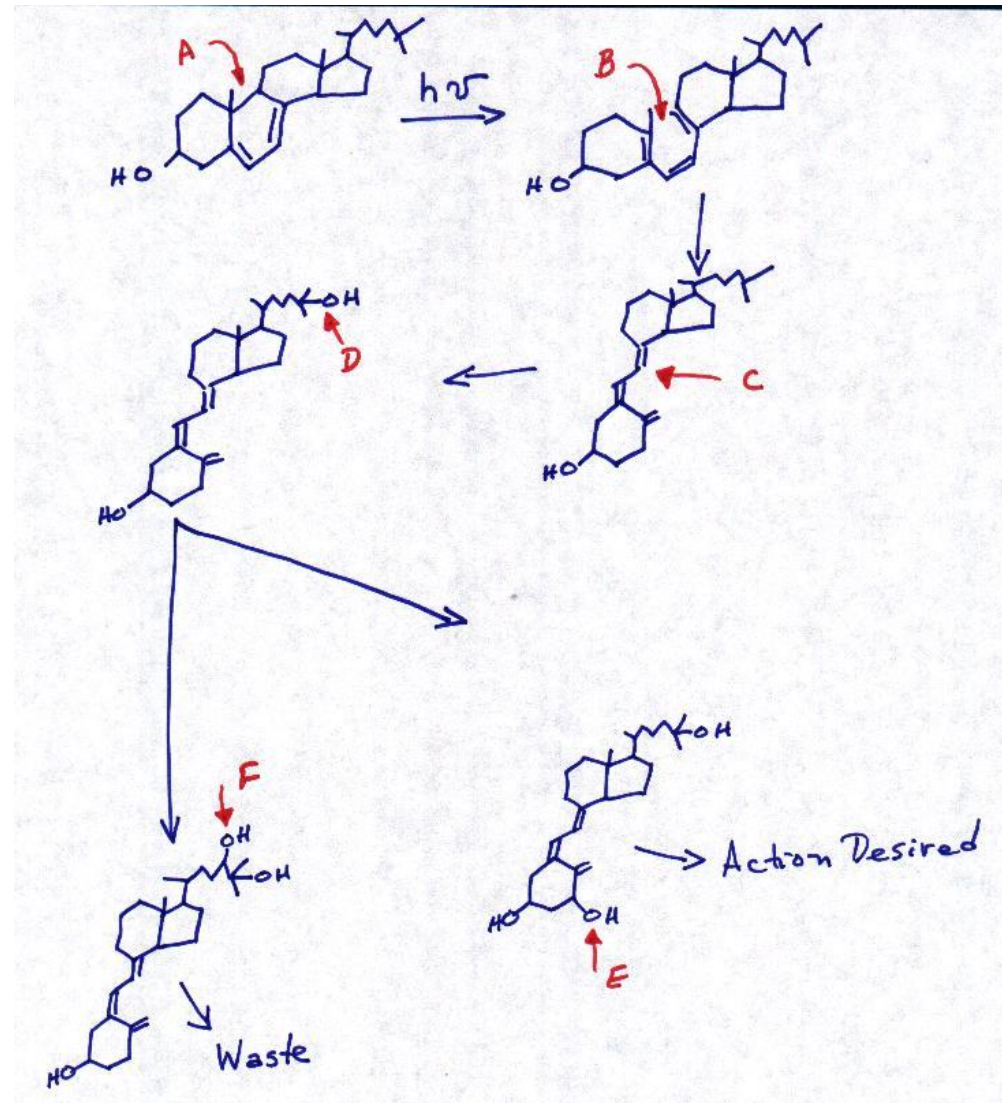
- The skin protects us from dehydration.
- It provides a protective layer from ultraviolet light by causing tanning.
- The skin participates in excretory functions, as well.
 - It allows for the excretion of small amounts of water and salts. Of course, if you're hiking to Mt. Rose in August, you are aware that it permits copious amounts of water and salt excretion by the wetness of your t-shirt and the salt deposits on the outside of your boots at the arch the following day.

Vitamin D

- The skin is the site of vitamin D synthesis.
- Vitamin D stimulates calcium and phosphate uptake from food for bone growth.
- Vitamin D is a hormone, i.e., it is produced in one part of the body and carried via the blood to exert its effect on a different part of the body.
- The synthesis of Vitamin D begins with the photolysis (fotolysis) of 7-dehydrocholesterol to pre-vitamin D₃.
- Pre-vitamin D₃ is then transported via a carrier protein to the liver where it is converted to 25-hydroxyvitamin D₃.
- This compound will either be stored in the liver or adipose tissue or will be transported to the kidney where it will be converted to 1 α , 25-dihydroxyvitamin D₃ -- the active form of vitamin D.
- Alternatively, the vitamin D will be inactivated and excreted via the kidneys, should we not need it.

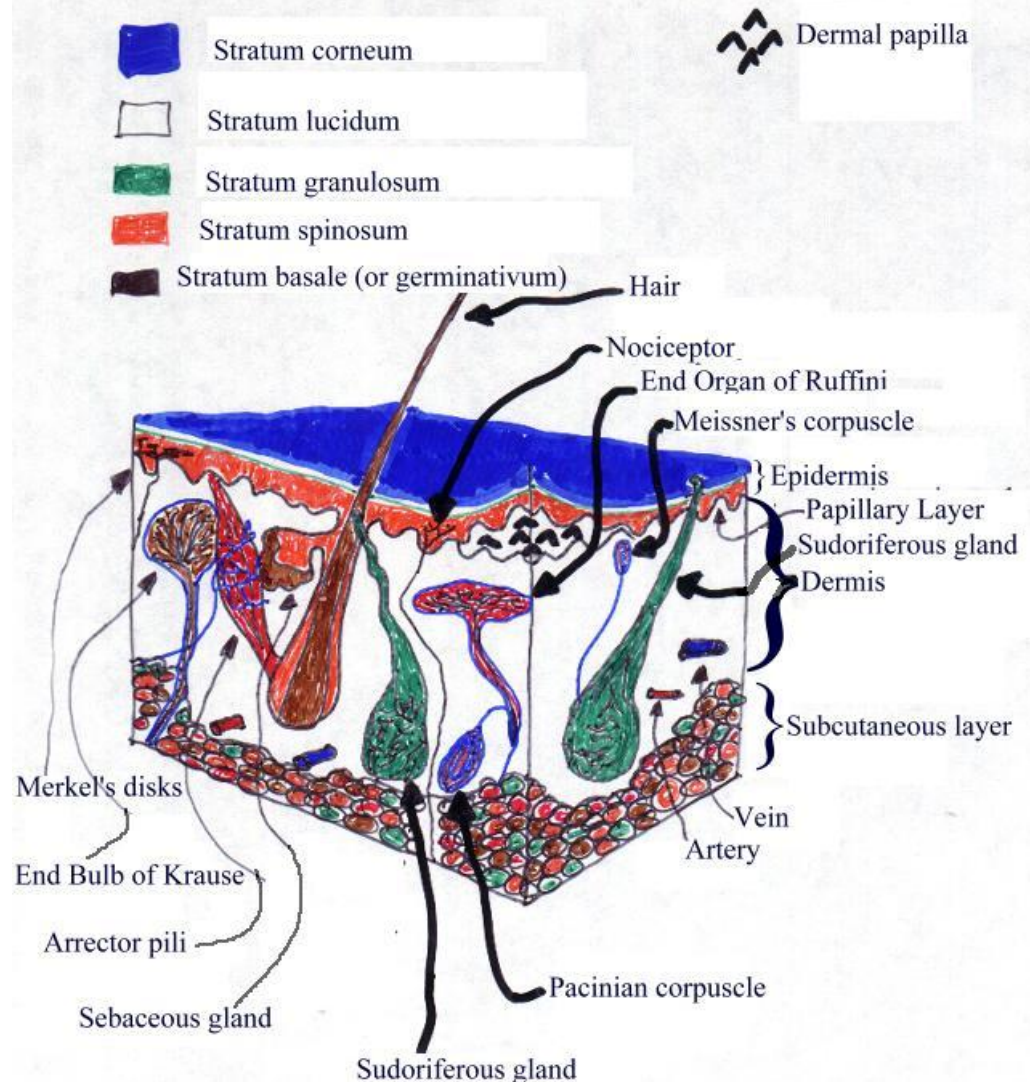
Vitamin D Synthesis

- **A)** shows the carbon-carbon bond that will be photolyzed in the skin,
- **B)** shows the intermediate after photolysis,
- **C)** shows the rearrangement of the molecule,
- **D)** shows the -OH group added by 25-hydroxylase,
- **E)** shows the 1α -OH group added by the 1α -hydroxylase and
- **F)** shows the -OH group added onto the #24 carbon by the 24R-hydroxylase to inactivate 25-hydroxyvitamin D₃.
- Product F is excreted as waste and Product E is the active form of the vitamin.



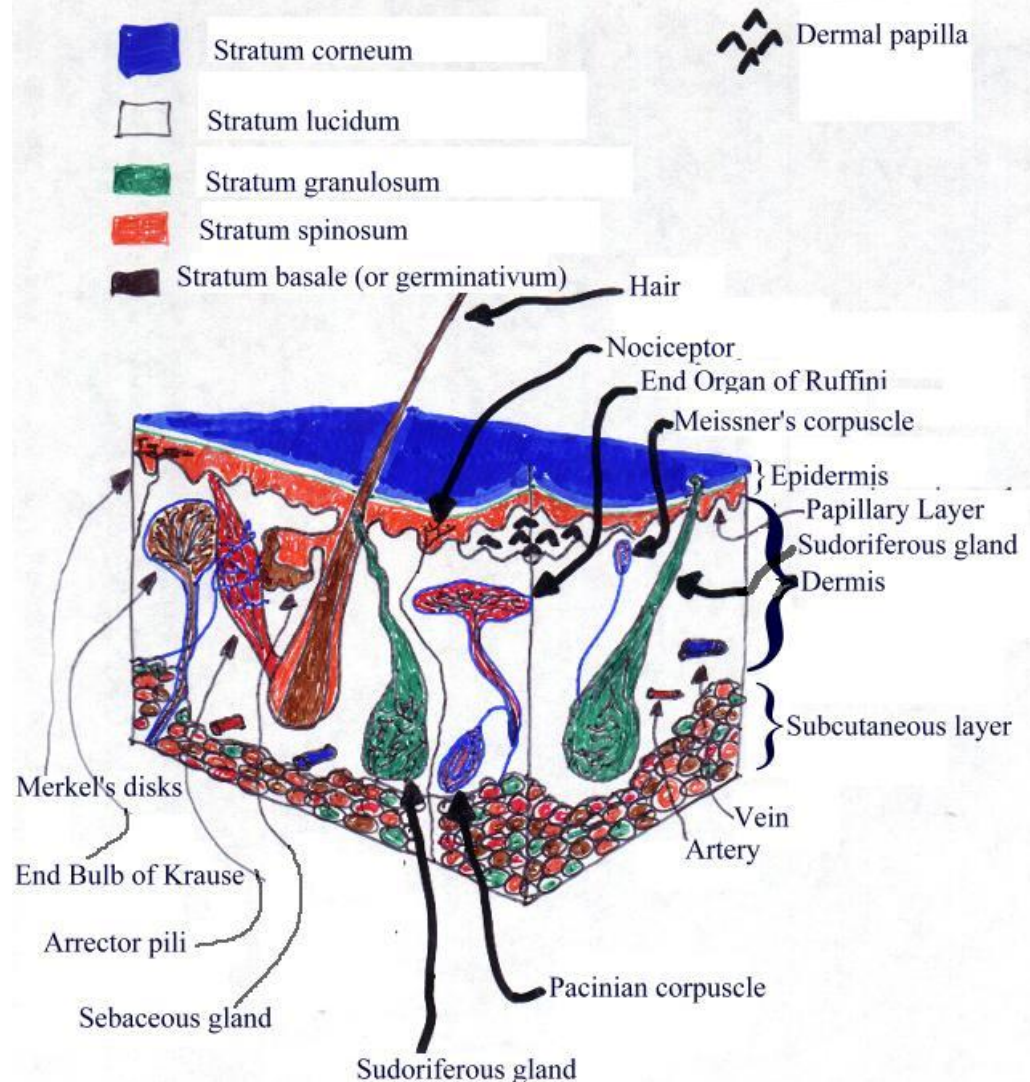
Skin

- The anatomy of a section of thick skin.
- A number of structures are identified.
- We'll begin by discussing the 5 layers of the epidermis (the outer layer of the skin).
- The outer-most layer of the epidermis is the stratum corneum (STRAH tumm CORE nee umm).
- This consists of 25-30 rows of flat, dead cells filled with keratin (CARE uh tinn; waterproofing protein).
- This layer is continuously shed and replaced.
- It is an effective barrier against light, heat waves, bacteria and chemicals.



Skin

- The anatomy of a section of thick skin.
- The second layer IN THICK SKIN is the stratum lucidum (LOO si dummm).
- It is not present in thin and hairy skin.
- It is typically, then, found in the palms and soles of hands and feet, respectively.
- It got its name because it's a clear layer.
- This layer consists of 3-5 rows of clear, flat, dead cells containing eleidin.



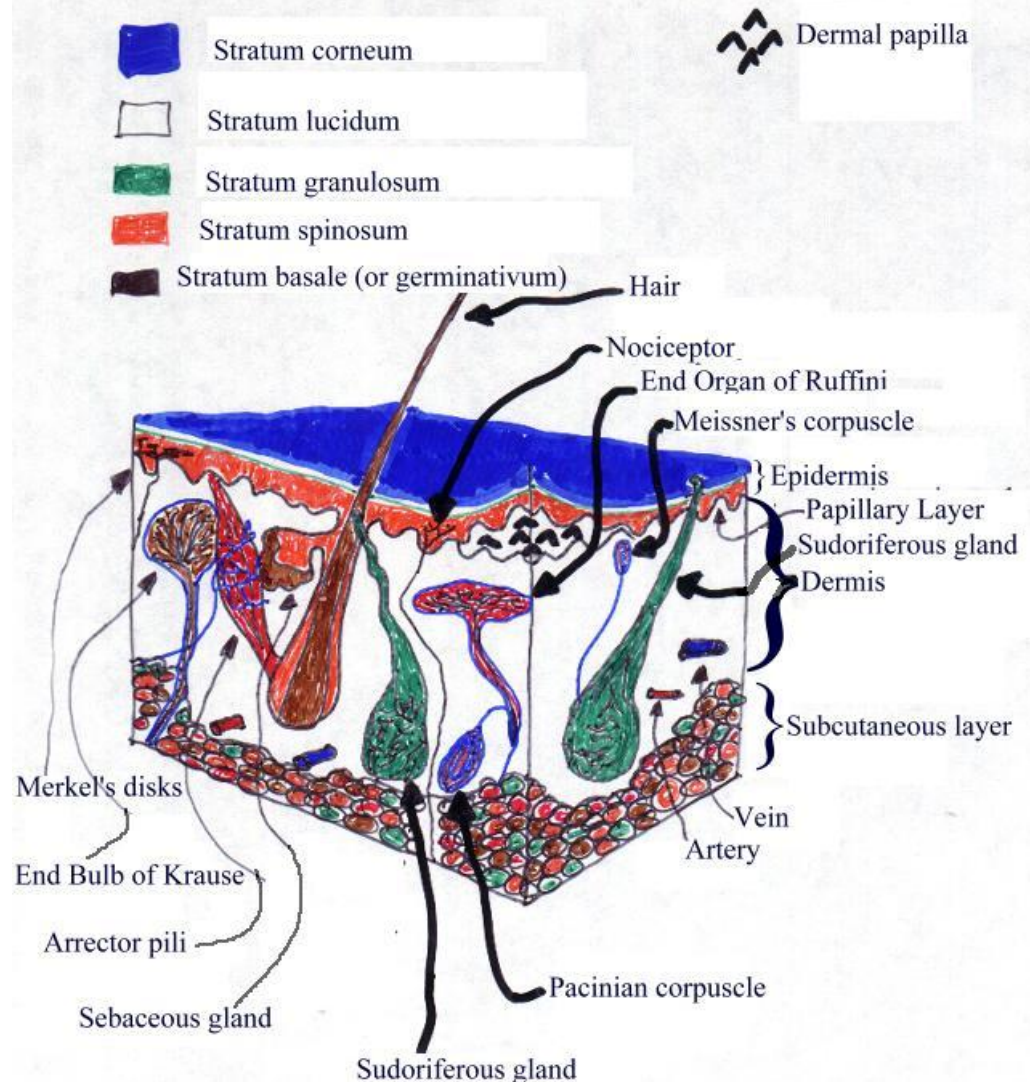
ASIDE

- The synthesis of keratin begins with keratohyalin (kurr AH toe HIGH uh linn) being chemically modified to form eleidin (ee lee I dunn), which is, in turn, modified to keratin.

END OF ASIDE

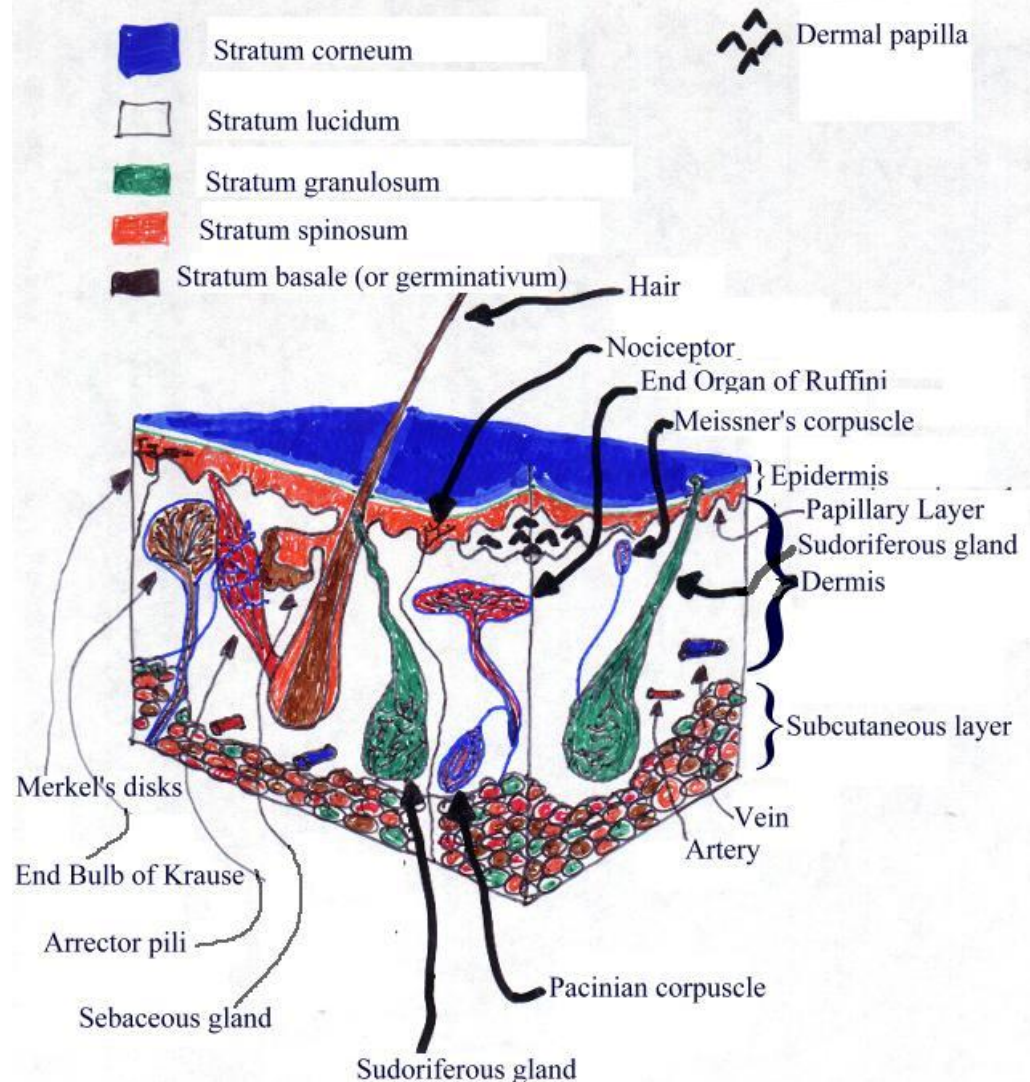
Skin

- The anatomy of a section of thick skin.
- The third layer down is the stratum granulosum (grann you LO summ).
- It consists of 3-5 rows of flattened cells containing keratohyalin (KH; dark staining granules).
- KH is involved in keratin formation as discussed above.



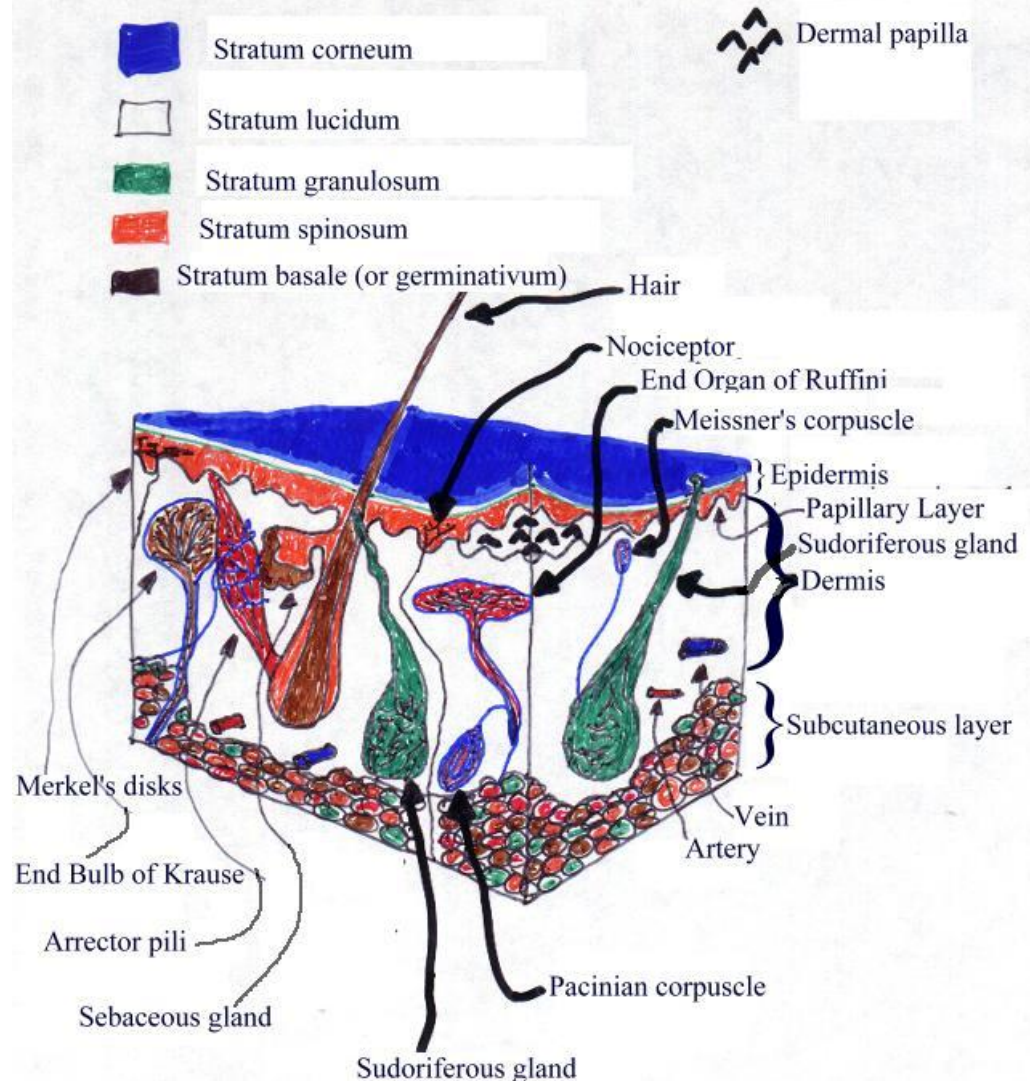
Skin

- The anatomy of a section of thick skin.
- The stratum spinosum (spuh NO summ), the next layer down, received its name as the cells in this layer have prickly spines on their surfaces that cause the cells to adjoin.
- This layer consists of 8-10 rows of polyhedral (many angled) cells.



Skin

- The anatomy of a section of thick skin.
- The deepest layer of the epidermis is the stratum basale (buh SALL ee) or stratum germinativum (jurr minn uh TEE vumm).
- This layer is a single layer of cuboidal/columnar cells, which undergo continual cell division.
- As the cells multiply, they push upward and become part of the layers on the top.
- The nuclei degenerate as cells move up.
- Cells die and sluff off.
- Other cells migrate DOWN into the dermis to form sweat and oil glands and hair follicles.
- The latter name of this layer is due to its role in germinating new cells.
- In hairless skin, this layer contains Merkel's discs.



Dermis

Papillary Layer

- Composed of connective tissue containing collagenous and elastic fibers.
- It is thickest over the palms and soles and on the dorsal and lateral body aspects.
- This layer consists of about 20% of the total dermal thickness.
- This layer of the dermis is also composed of areolar (air ee OH lurr) tissue (loose connective tissue) with fine elastic fibers.
- Its surface area is greatly increased by the presence of dermal papillae.
- These papilla project into the epidermis and may have capillary loops in them.
- Some papilla contain Meissner's corpuscles.
- The dermal papillae cause fingerprints and toeprints.

Reticular Layer

- The deeper layer of the dermis is the reticular layer.
- This layer contains numerous imbedded blood vessels, nerves, glands and hair follicles.
- It is thinnest over the eyelids, penis, scrotum, and the ventral and medial body surfaces.
- It makes up the remaining 80% or so of the dermis.
- This layer also contains dense irregularly oriented connective tissue with interlacing bundles of collagenous (kuh LOJJ uh nuss) and coarse elastic fibers.
- It's called reticular (rete = net) due to the bundles of collagenous fibers that interlace in a net-like manner.
- The interfiber spaces contain small quantities of fat, hair follicles, nerves, oil glands and ducts of sweat glands.
- THIS region, among other factors, leads to differences in skin thicknesses over the body.
- Collagen and elastic fibers provide for strength, extensibility (ability to stretch) and elasticity (ability to return to original shape after extension or contraction).

Examples of Extensibility

- 1) pregnancy: stretch marks turn from red to silvery white with time and are called striae (STRY ee);
- 2) obesity: being overweight causes the skin to stretch and to even get striae;
- 3) edema (uh DEE muh): extracellular fluid in extremities that causes swelling.

Dermis: Reticular Layer

- The reticular layer of the dermis is attached to bone and muscle by the subcutaneous (SC, SQ, sub-q) layer.
- The SQ layer contains Pacinian corpuscles.

6 Different Receptor Organs Found in The Skin.

TEMPERATURE

- Krause's (KROW cez) end bulbs are temperature detectors.
- They are sensitive to cold and are activated at temperatures below 20° C (68° F).
- Ruffini's (ruh FEE neez) corpuscles are most sensitive in the range of 25-45° C.
- When these receptors are activated, the brain interprets this as a painful burning sensation.

PRESSURE

- Pacinian corpuscles are pressure receptors.
- They are naked nerve endings in deeper tissue.
- They are found in the SQ under skin and mucous membranes, around joints, in mammary glands and in the external genitalia of both sexes.

6 Different Receptor Organs Found in The Skin.

PAIN

- Nociceptors are pain receptors.
- They are naked nerve endings in all tissues in the body.
- They may respond to any type of stimulation.
- While receptors for somatic (soe MATT ick; the body) and visceral (VISS er ull) pain are similar, they are sufficiently different that SOMATIC pain is felt where it is, but VISCERAL pain is often felt away from the source organ. This is called referred pain.

TOUCH

- Merkel's discs are touch receptors.
- They are for discriminative touch (to be able to recognize exactly which part of the body is being touched).
- They are most numerous in the fingertips, palms, tip of tongue, lips, nipples, clitoris and tip of penis.
- The End Organs of Ruffini detect heavy and continuous touch sensations.

Skin Pigmentation -- Melanin

- Skin color depends on several pigments. The first pigment for discussion is melanin (MELL uh ninn).
- This is an epidermal pigment.
- The amount of melanin yields colors between pale yellow and black.
- Melanin is synthesized in melanocytes (muh LANN oh sites) just beneath or between the strata basale and spinosum.
- Melanocytes are derived from melanoblasts.
- Maximal numbers of melanocytes are found in mucous membranes, the penis, nipples and areola, labia, face and extremities.
- The number of melanocytes is about the same in ALL races.
- The differences in skin color are due to the amount of pigment produced and dispersed.

Skin Pigmentation -- Melanin

- Melanin is synthesized from the amino acid tyrosine in the presence of an enzyme (biological catalyst) called tyrosinase (tie ROW sinn ace).
- With increased ultraviolet exposure, tyrosinase activity increases in melanocytes and yields increased melanin production.
- Cell bodies (of the melanocytes) send out long processes between epidermal cells.
- Upon contact with the processes, the melanin is taken up by the epidermal cells by phagocytosis.
- If more UV light is encountered, the process is repeated which leads to high amounts of melanin and tanning.

Skin Pigmentation -- Melanin

- Tanning is a vital protective function of the skin: it protects the body from radiation.
- Tanning is also a double-edged sword: increased tanning decreases the efficiency of photolysis of 7-dehydrocholesterol to pre-vitamin D₃.
- The synthesis and distribution of melanin within the epidermis is regulated by a hormone from the anterior pituitary gland called melanocyte-stimulating hormone (MSH).
- The only problem with MSH is that it's possible that it's a biologically active ARTIFACT that has no homeostatic role in humans.

Skin Pigmentation -- Carotene

- Carotene (KARE oh teen) is a dermal pigment.
- It is a precursor to vitamin A found in carrots.
- It's found in the stratum corneum and fatty regions of the dermis in Asians.
- Carotene and melanin account for the yellowish hue of their skin.

Skin Pigmentation -- Blood

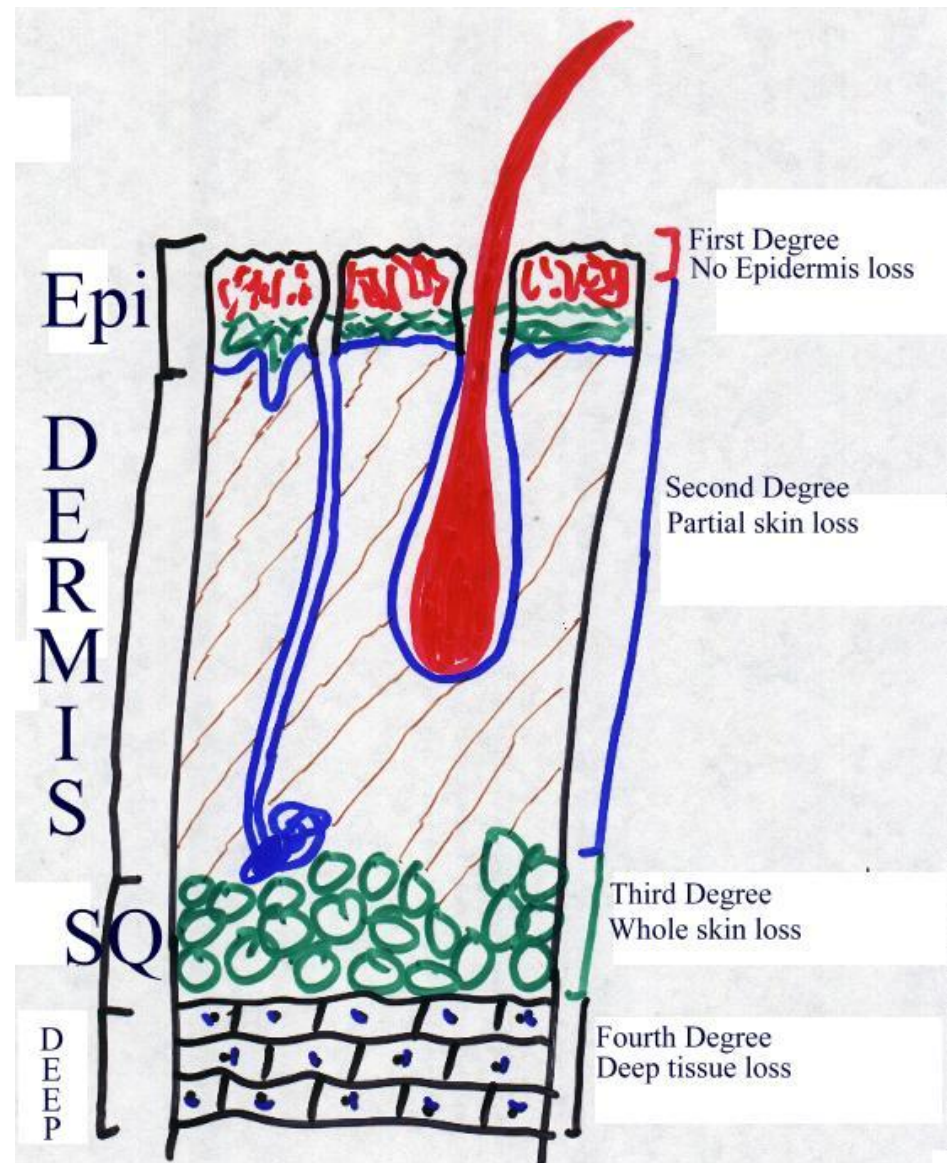
- Blood in dermal capillaries is what makes Caucasian skin appear pink.
- This coloration is due to the fact that the redness of the vessels is not heavily masked by pigment.
- The epidermis has NO blood vessels, BTW.
- This is a characteristic of ALL epithelia.

4 Pigment Alterations of Fundamental Significance

Albinism	Albino	Vitiligo	Freckles
The inherited inability of an individual in any race to produce melanin; pigment is absent in skin, hair, eyes.	One with albinism.	Any or all loss of melanocytes from skin regions which causes patchy, white spots.	Patches of stored melanin

Skin Burns

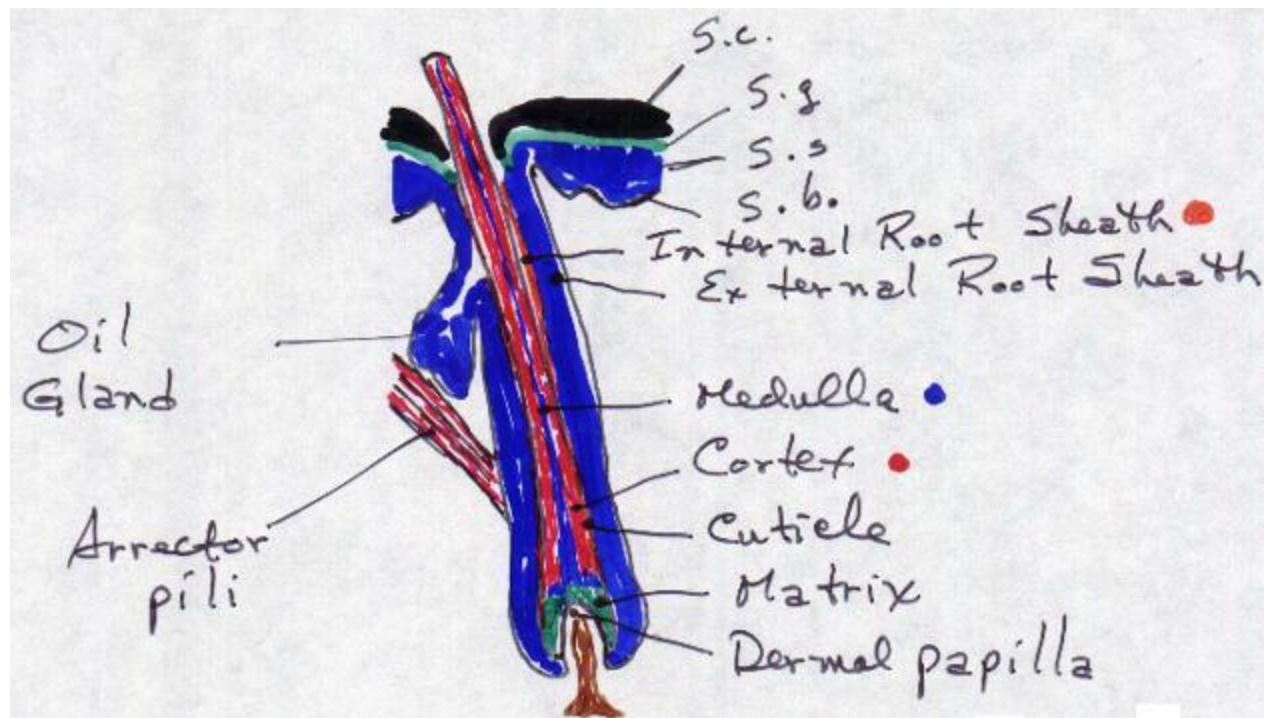
- **First-degree burns** are the general, run-of-the-mill sunburn types of burns.
 - Typically there is no loss of epidermis -- only a layer or so of the epidermis when you peel.
- **Second-degree burns** cause partial skin loss and are characterized by blistering.
- **Third degree burns** cause whole skin loss.
 - These typically do not hurt as the nerves have been destroyed, as well.
 - HOWEVER, when the nerves begin to grow back during healing, it hurts like hell!
- Fourth degree burns cause deep tissue loss.



BURN CLASSIFICATION

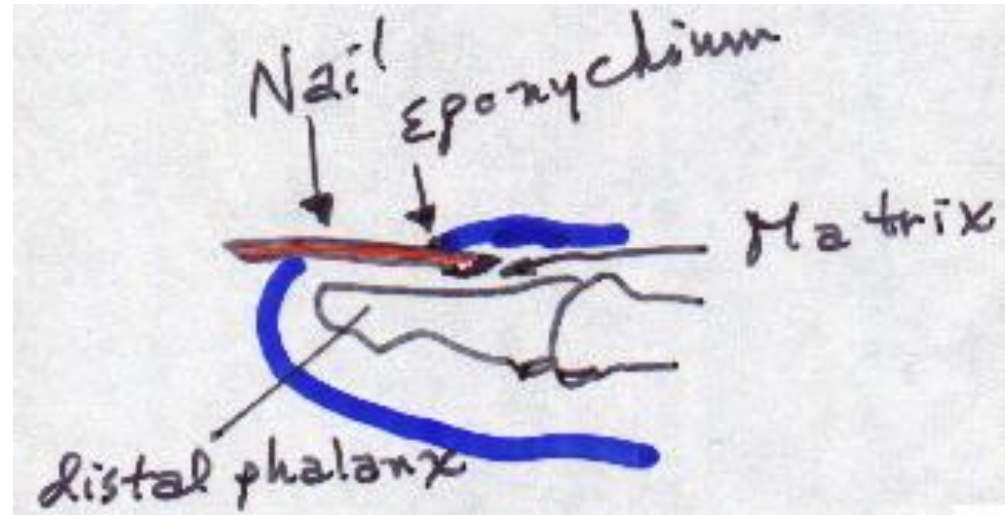
Epidermal Derivatives

Hair



External Root Sheath	Downward continuation of the strata basale and spinosum; at the follicle, only the stratum basale wraps underneath it.
Internal Root Sheath	Formed from the matrix to give a tubular sheath deep to the external root sheath.
Cuticle	A single layer of thin, flat, scale-like cells with greatest amount of keratinization. They are shingle-like with the free edge UP.
Cortex	The major part of the shaft. They are elongated cells. This region contains pigment in dark hair; air in white hair.
Medulla	Polyhedral cells that contain eleidin and keratin.
Matrix	The germinal layer that produces new hairs by cell division within the SAME follicle.
Papilla	Loose connective tissue.

Nails



Free edge	Nail body	Eponychium (epp oh KNEE kee umm)	Lunula (LOON you luh)	Nail root
Portion of the nail beyond the end of the digit.	Portion of the nail, which is visible.	Aka cuticle; a narrow band of epidermis that adheres to the nail.	Whitish, semi-lunar area of proximal end of nail.	Hidden portion of the nail in the proximal nail groove.

The Last Epidermal Derivatives: The Glands

- Sebaceous [suh BAY shuss; oil],
- Sudoriferous [sew durr IFF urr uss; sweat] and
 - Ceruminous [sur ROOM inn uss; wax]

Sebaceous Glands

- Sebaceous glands are connected to hair follicles mostly.
- The ones at the hair open into the neck of the follicle, while those few that are away from hair open directly onto the skin.
- The latter are found on the glans penis, labia minora, lips and eyelids.
- Small sebaceous glands are found over the trunk and extremities.
- Large sebaceous glands are found in the skin of the breasts, face, neck and upper chest
- (remember your own days of acne -- where were the lesions mostly?)
- Sebaceous glands secrete sebum, which is a mixture of fats, cholesterol, protein and salts.
- This keeps the hair from drying and becoming brittle.
- It also prevents excessive water loss by evaporation.
- Sebum softens skin and inhibits the growth of some bacteria.

Sudoriferous Glands

- There are two (2) kinds of sudoriferous glands:
- Apocrine (AH poe krin) and Eccrine (ECK rinn).
 - **Eccrine glands are more common.**
 - They are simple, coiled, tubular glands.
 - They are everywhere **EXCEPT** the margins of the lips, nail beds, glans penis, glans clitoris, labia minora and eardrums.
 - The greatest numbers are in the palms and soles.
 - **They secrete a watery sweat.**
 - The secretory portion of these glands is in the SQ; the excretory portion opens at the epidermal surface.
- **Apocrine glands are simple, branched tubular glands.**
- They are found in the axillary, pubic and areolar regions of the body.
- **These glands are activated at puberty.**
- **They secrete a viscous ("sticky") sweat.**
- Their secretory portion is in the dermis or SQ; the excretory portion opens into the hair follicle.

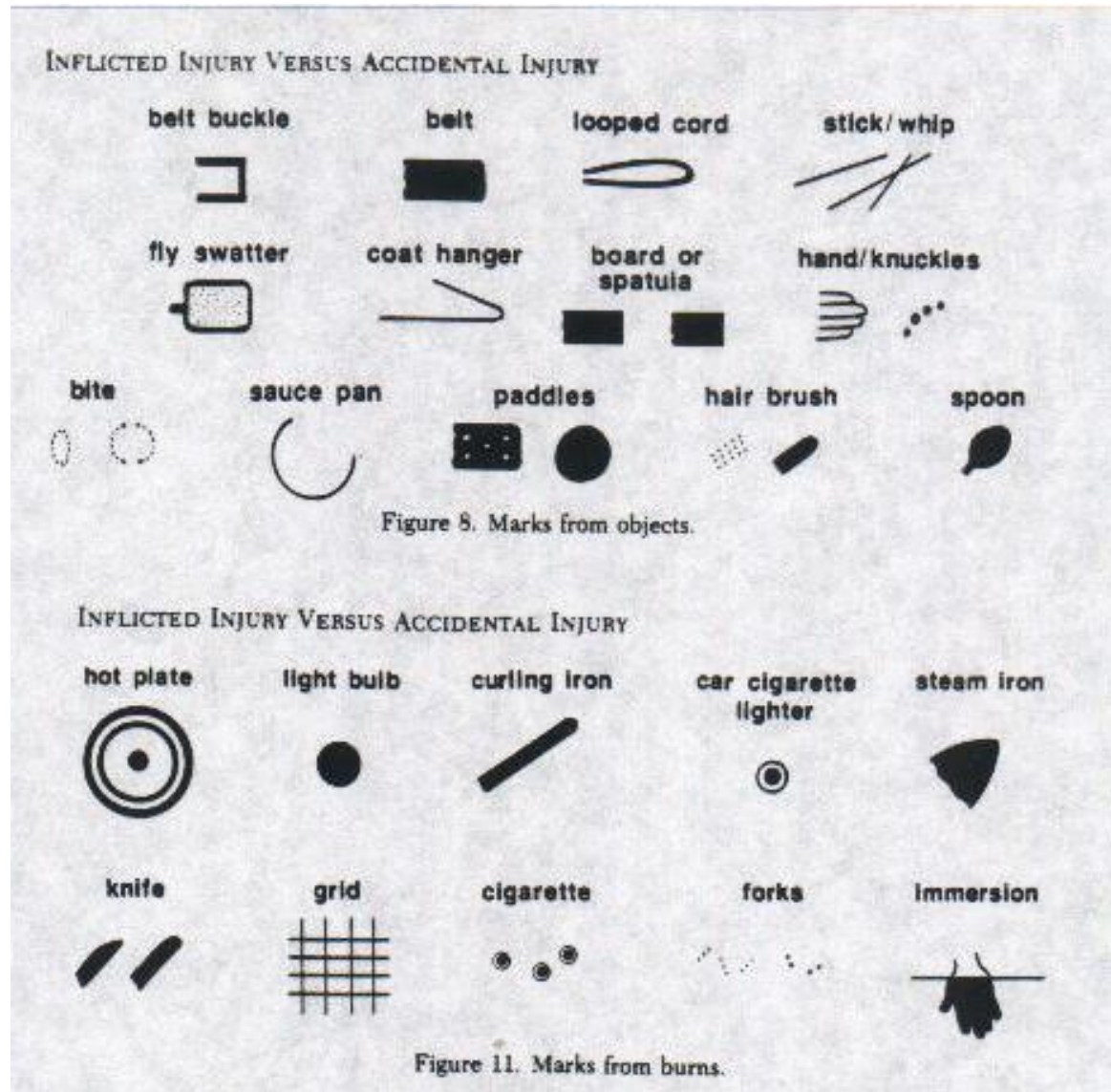
Sweat

- The sweat from these glands contains water, salts (primarily sodium chloride), urea, uric acid, amino acids, ammonia, glucose, lactate and ascorbate -- bacteria LOVE these, which is why we stink if we don't bathe/shower regularly.
- The primary function of these glands is to regulate temperature via evaporation.
- A secondary function is to help eliminate waste products.

Ceruminous Glands

- Ceruminous glands are modified sudoriferous glands in the external auditory meatus
 - (where you stick your finger {**NEVER** use q-tips, bobby pins, matchstick, baling wire, etc} to get the wax out of).
- They lie in the SQ, deep to the sebaceous glands.
- Ceruminous plus sebaceous secretions give cerumen (suh ROO munn; wax).
- In conjunction with hair, wax provides a sticky barrier that prevents the entrance of foreign bodies into your ear that might mess with your hearing.

Inflicted Injury Marks



Inflicted Injury Marks

Table 5. Time Required to Cause First- or Second-Degree Burns on Human Skin

WATER TEMPERATURE* (°C [°F])	TIME OF EXPOSURE (seconds)
52 (125.6)	70
54 (129.2)	30
56 (132.8)	14
58 (136.4)	6
60 (140)	3
62 (143.6)	1.6
64 (147.2)	1

Adapted from Moritz AR, Henriques FC: Studies of thermal injury: Pathology and pathogenesis of cutaneous burns experimental study. Am J Pathol 23:915-941, 1947.

Borrowed from Pediatric Clinics of North America
August 1990 Issue

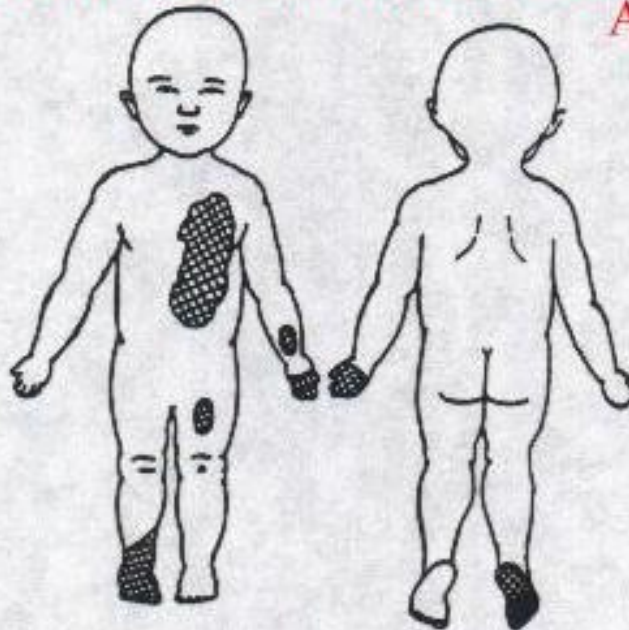


Figure 1. Burn diagram of patient. Full-thickness burns (left hand, thorax, right foot) and partial-thickness burns (left wrist, left thigh) comprised approximately 11% of body surface area. (From Alexander RC, Surrell JA, Cohle SD: Microwave oven burns to children: An unusual manifestation of child abuse. Pediatrics 79:2, 255-260, 1987; with permission.)