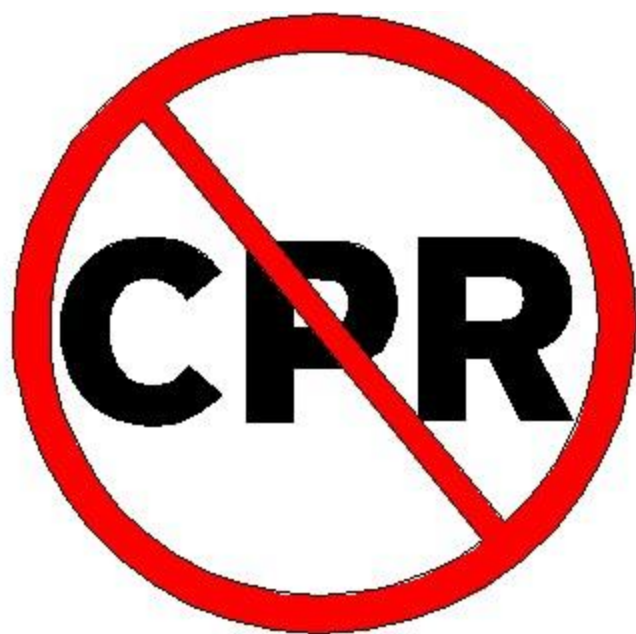



**Do Not
Resuscitate**

The Respiratory System

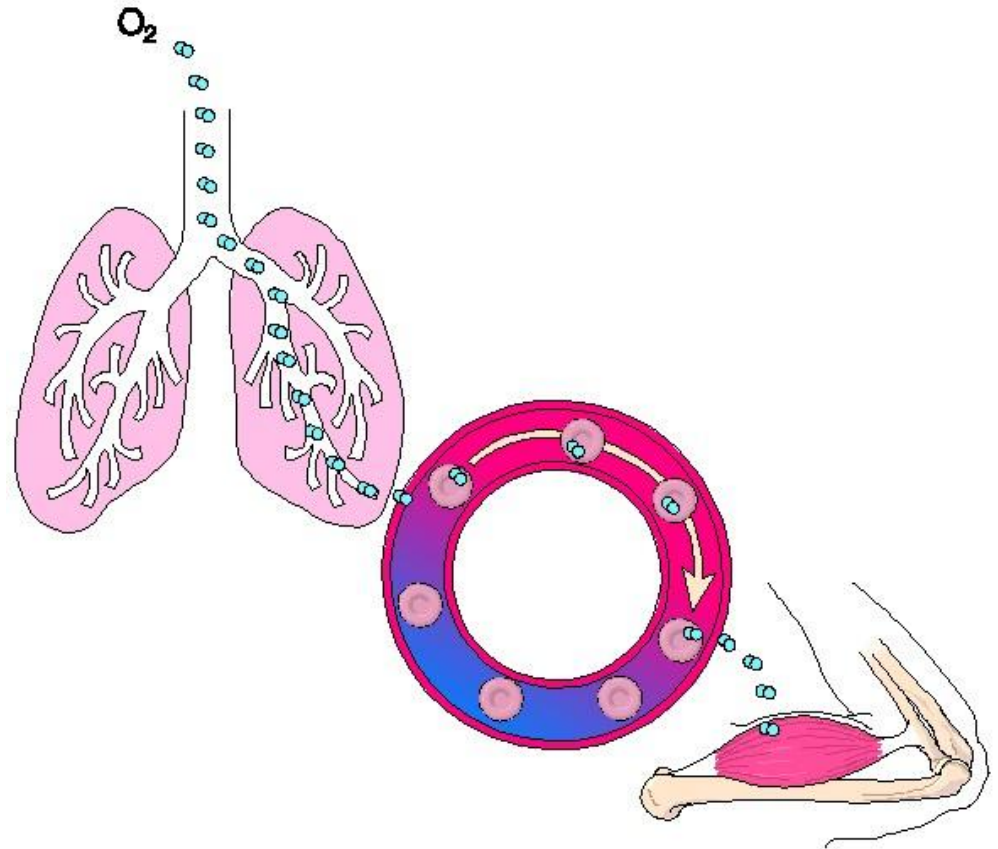
And Shock

Otorhinolaryngology (ENT)

- The branch of medicine that deals with the diagnosis and treatment of diseases of the ears, nose and throat

Respiratory System Constituents

- Consists of nose, pharynx, trachea, bronchi, lungs
- Upper respiratory system: nose, throat and associated structures
- Lower respiratory system: the remainder



Respiration: the overall exchange of gases between the atmosphere, blood and cells

1. Pulmonary ventilation

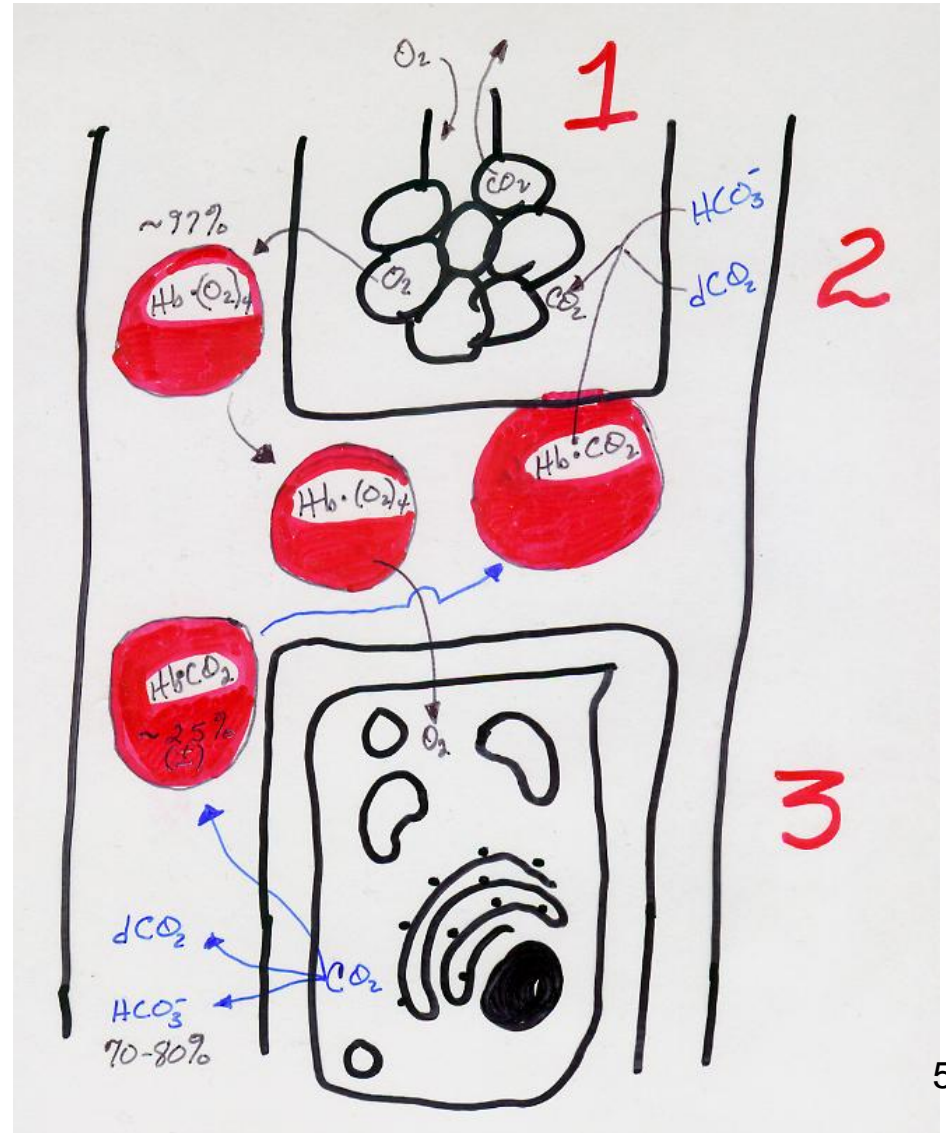
1. aka breathing; the inspiration and expiration of air between the atmosphere and lungs

2. External respiration

1. Exchange of gases between lungs and blood

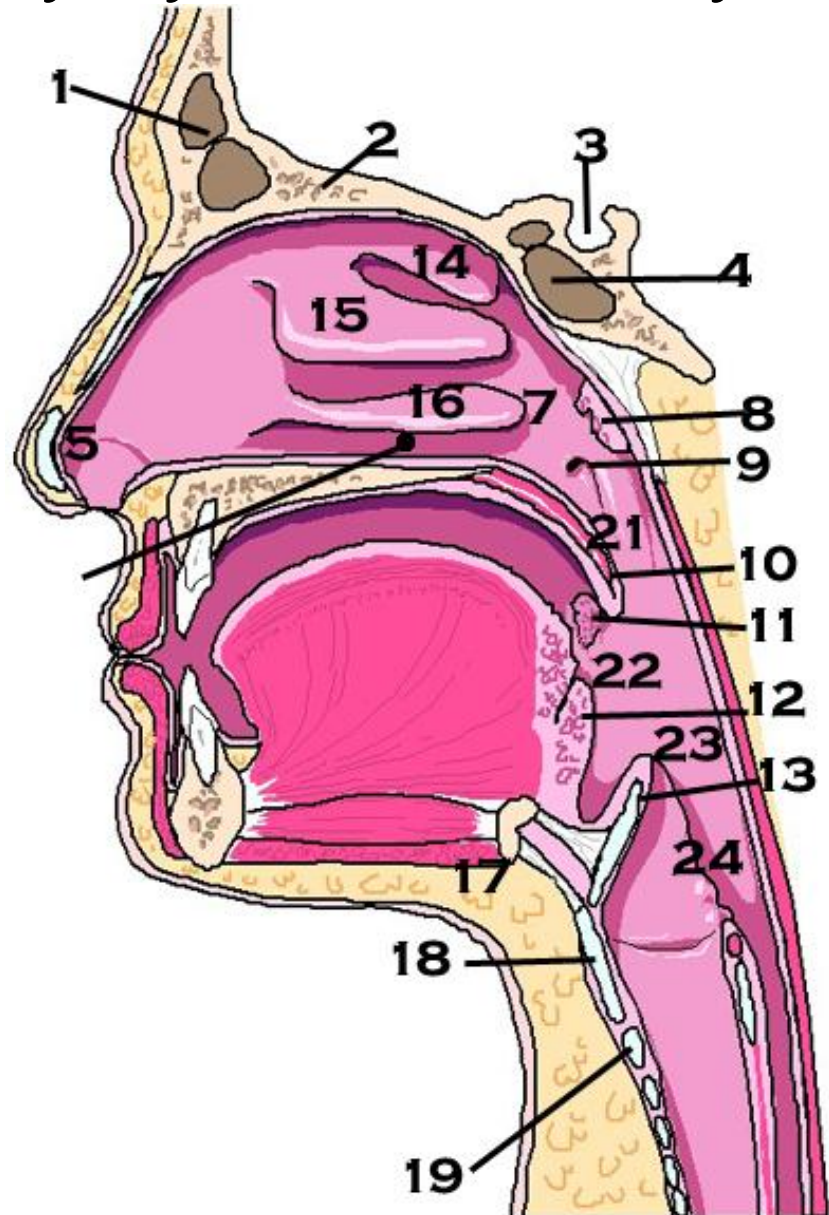
3. Internal respiration

1. Exchange of gases between blood and cells



Upper Respiratory System Anatomy

1. Frontal sinus
2. Cribriform plate
3. Sella turcica
4. Sphenoidal sinus
5. Vestibule
6. **Inferior meatus – line**
7. Internal nares
8. Pharyngeal tonsil (adenoid)
9. Eustachian tube
10. Uvula
11. Palatine tonsil
12. Lingual tonsil
13. Epiglottis
14. Superior turbinate
15. Middle turbinate
16. Inferior concha
17. Hyoid bone
18. Thyroid cartilage
19. Cricoid cartilage
20. **Not here**
21. Nasopharynx
22. Fauces
23. Oropharynx
24. Laryngopharynx



Organ Descriptions

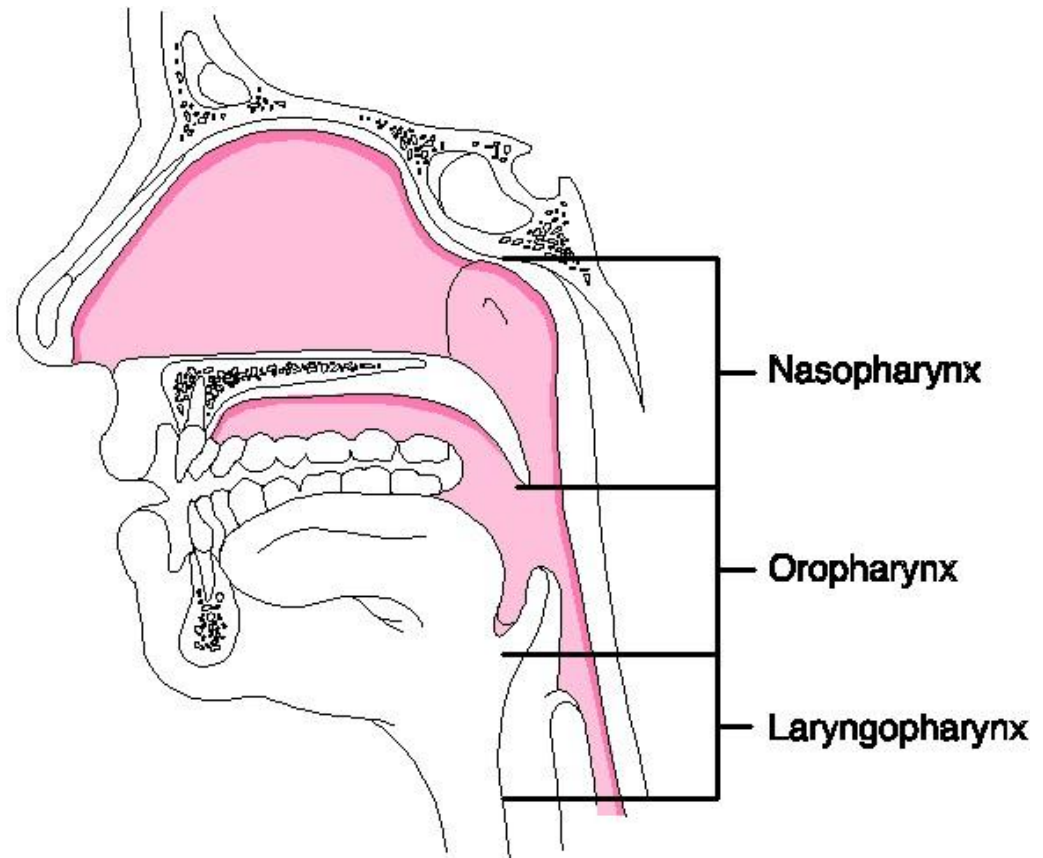
- External nares = nostrils
- Internal nares = 2 openings in the back of the interior nose which allow for communication with the throat
- Nasal septum = cartilage; separates nostrils
- Vestibule = anterior portion of the nasal cavity just inside the nostril
- Olfactory region = the area superior to the superior nasal conchae (shelves) with olfactory receptors in the membrane lining

Organ Descriptions

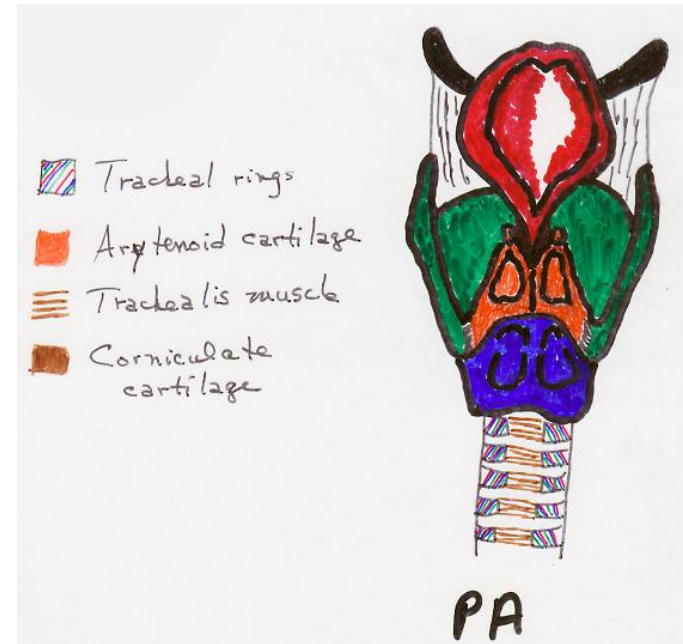
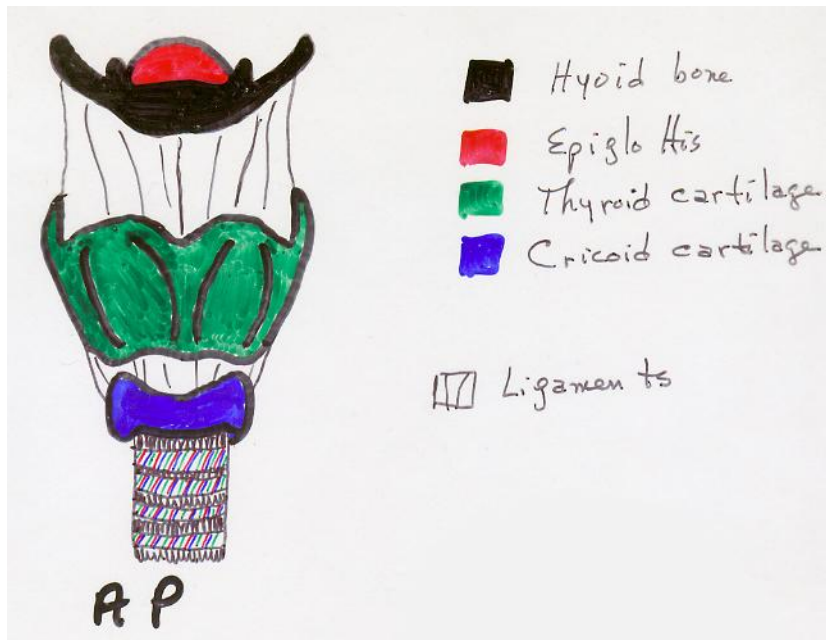
- Interior structures of nose are specialized for three functions:
 1. Warming, moistening and filtering incoming air
 2. Olfactory stimuli are received
 3. Large hollow resonating chambers are provided for speech sounds

Organ Descriptions -- Pharynx

- **aka throat** = funnel-shaped tube which starts at the level of the internal nares and ends at the level of the cricoid cartilage
- **Nasopharynx:** the uppermost portion of the pharynx; have 4 openings into this area: two internal nares and the openings to the Eustachian tubes; posterior wall also contains the adenoids
- **Oropharynx:** middle portion of the pharynx, from soft palate to hyoid bone; only one opening: fauces (opening from the mouth); two pairs of tonsils are found here: palatine and lingual
- **Laryngopharynx:** lowest portion of the pharynx; extends from hyoid bone to esophagus and larynx (voice box)

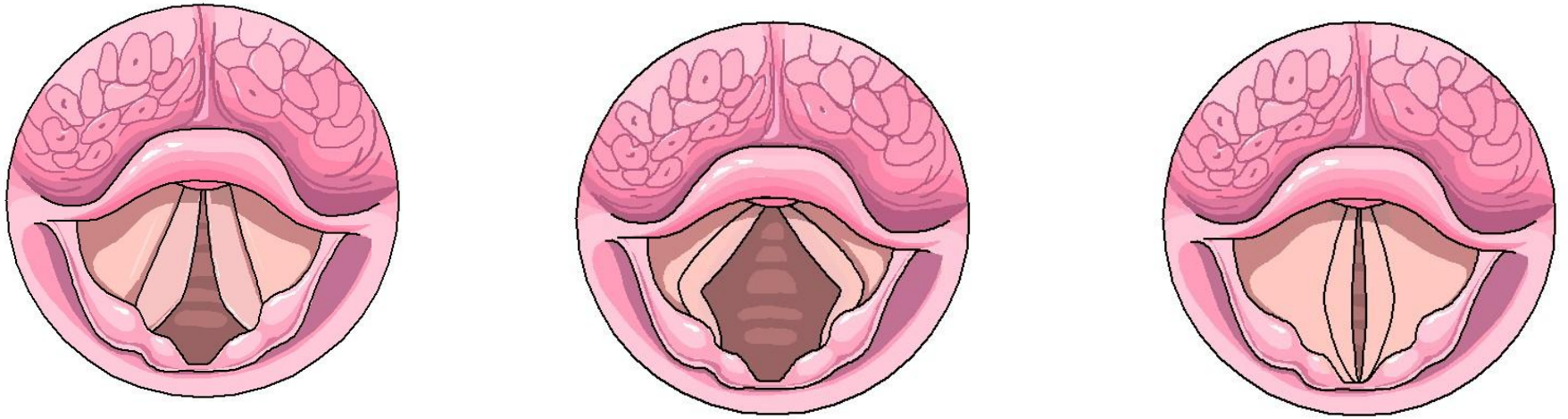


Larynx: aka voice box; midline, between C₄ and C₆; composed of 9 pieces of cartilage



- Thyroid cartilage: Adam's apple; 2 fused plates which give it its characteristic triangular (shield) shape; larger in males than in females (1 piece).
- Epiglottis: leaf-shaped cartilage which lies on top of the larynx. During swallowing, the larynx elevates and the free edge of the epiglottis forms a lid, preventing food or other foreign objects from dropping into the larynx. This "lid" fits over the glottis (1 piece).
- Cricoid cartilage: a ring of cartilage which forms the inferior wall of the larynx (1 piece).
- Arytenoid cartilage: pyramidal in shape and located at the superior border of the cricoid cartilage; attach to vocal folds and intrinsic pharyngeal muscles and can move the vocal cords (2 pieces).
- Corniculate cartilage: cone shaped; one is located at the apex of each arytenoid cartilage (2 pieces).
- Cuneiform cartilage: club shaped; anterior to corniculate cartilages (2 pieces). **Not in this view**

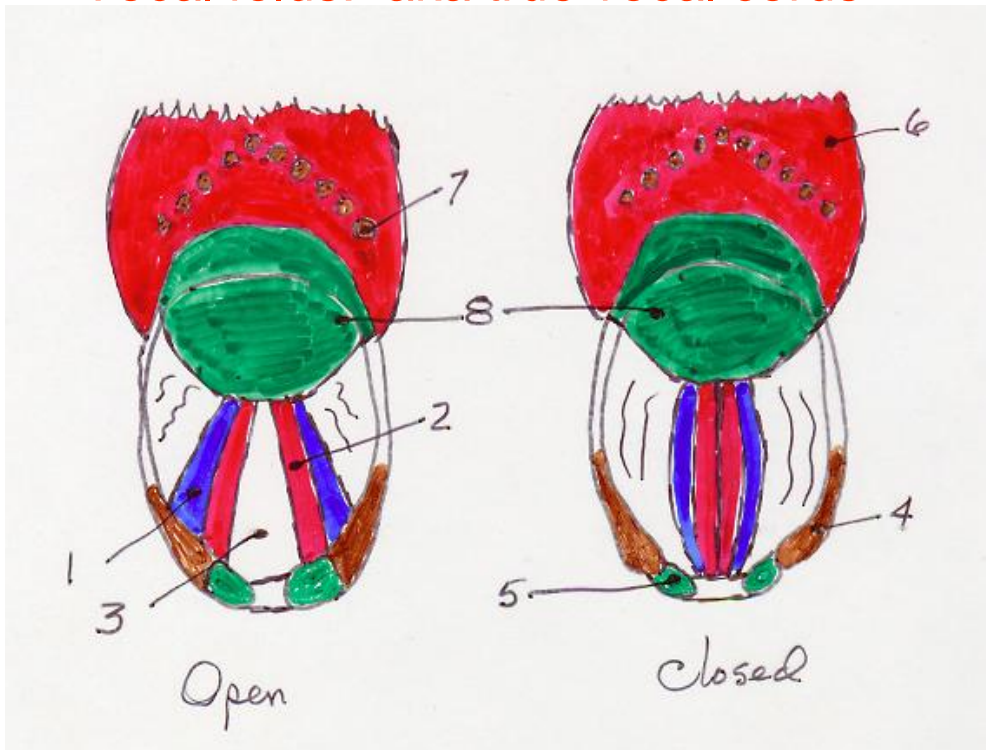
Voice/Sound -- Larynx



Normal inhalation, LEFT
Deep inhalation, CENTER
Phonation, RIGHT

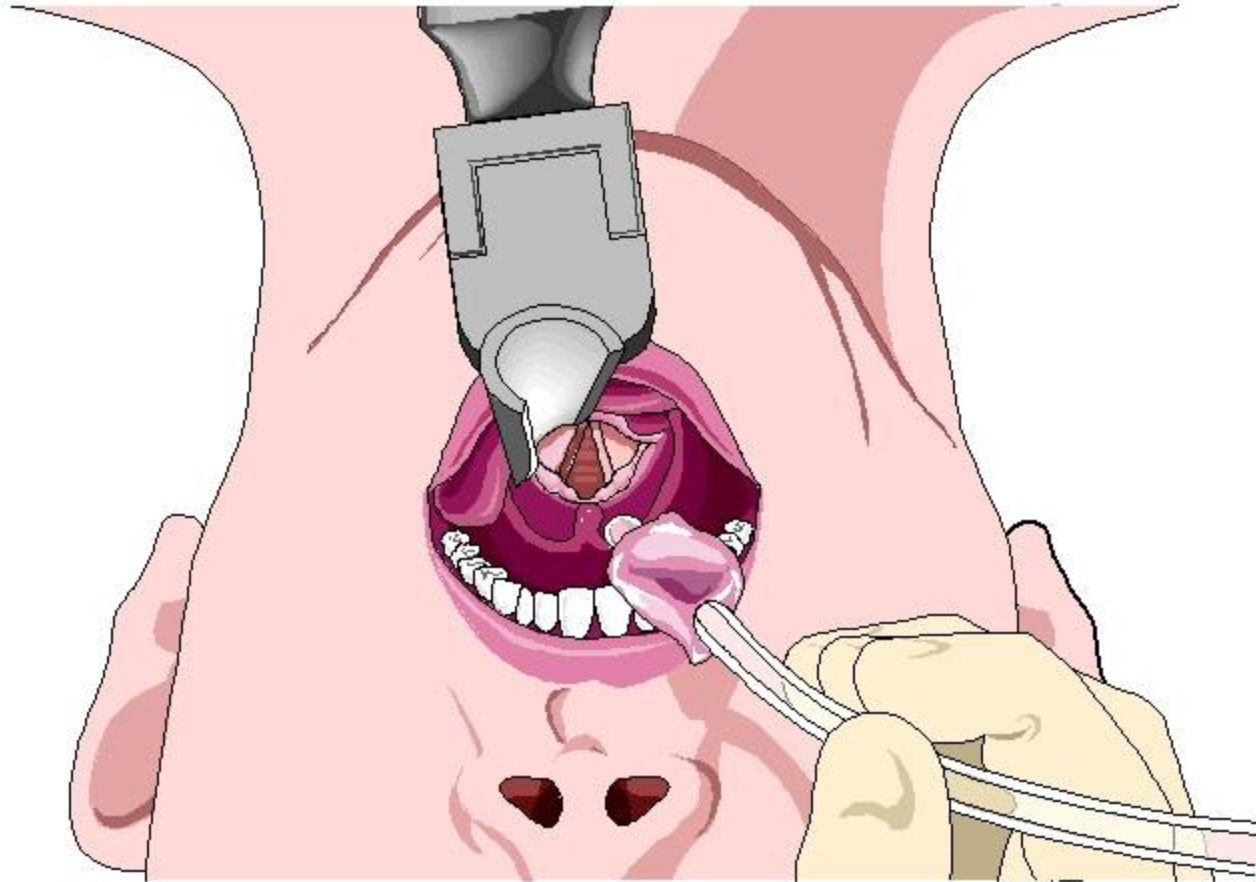
Voice/Sound -- 2

- Glottis: the space between the true vocal cords in the larynx; when anything but air progresses through the glottis, a cough reflex is elicited to expel the contents
- Ventricular folds: aka false vocal cords; upper pair of folds in larynx; function in holding breath against thoracic cavity pressure such as when a person exerts a strain while lifting something heavy
- Vocal folds: aka true vocal cords

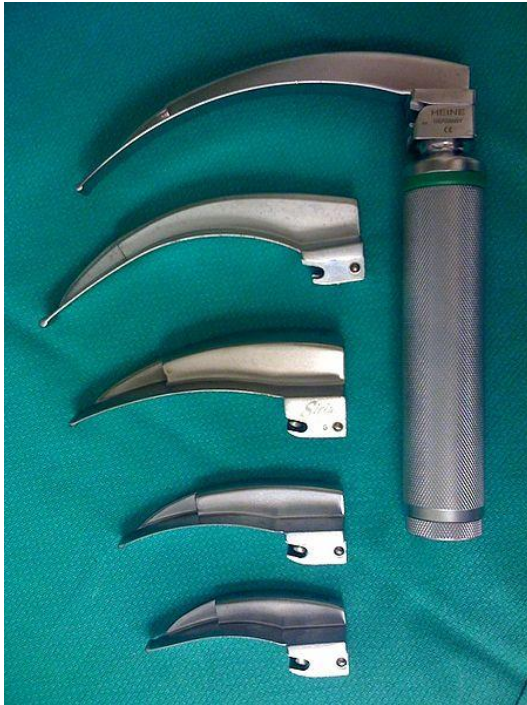
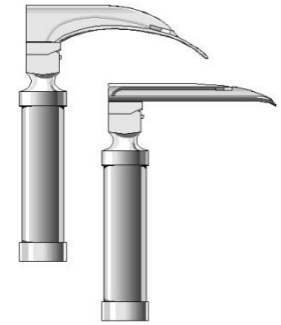
1. False vocal cords
2. True vocal cords
3. Glottis
4. Cuneiform cartilage
5. Corniculate cartilage
6. Tongue
7. Circumvallate papilla
8. Epiglottis

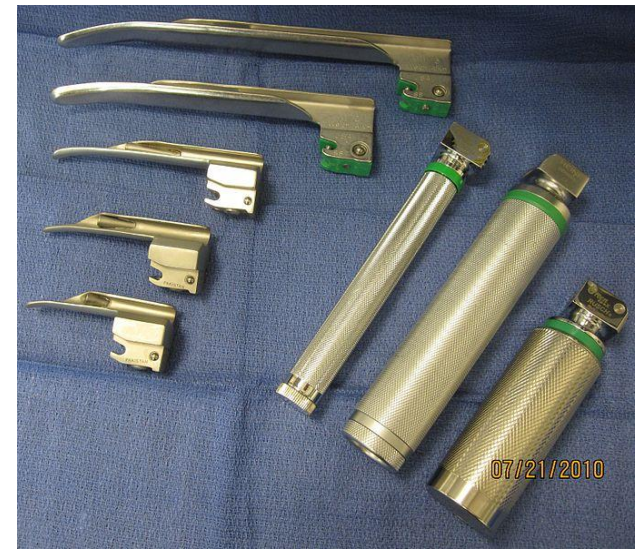A Laryngoscope's View of the Vocal Cords



Laryngoscope



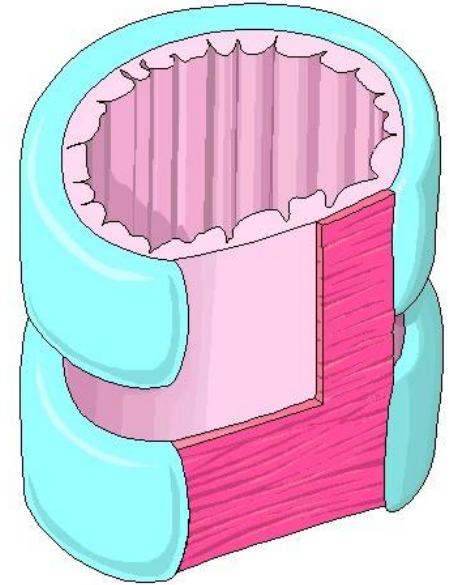
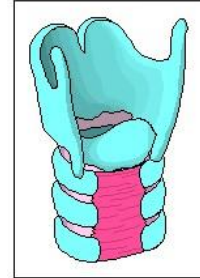
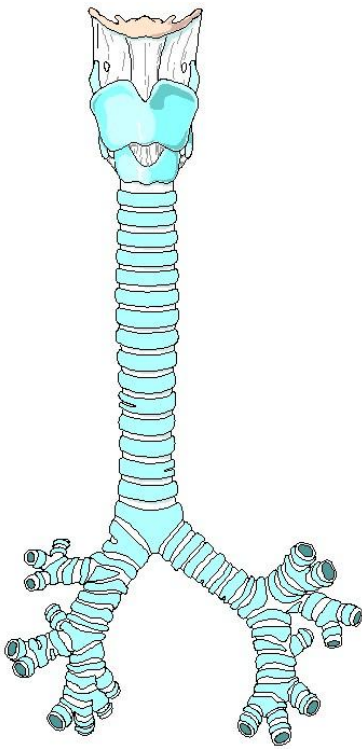
- Curved (Macintosh) or straight (Miller) blades depend on the person using the scope
- Preferences vary – may want a curved blade with a straight (more or less) extension



Vocal Folds

1. Attached to muscles and ligaments which allow them to be stretched to narrow the glottis.
2. If air is routed against the vocal cords, they vibrate and set up sound waves in the pharynx, nose and mouth.
3. The greater the PRESSURE of air, the louder the sound.
4. PITCH is controlled by the vocal fold tension.
5. If pulled taut by the muscles, they vibrate more rapidly and a higher pitch results
6. Lower sounds are the opposite.
7. Vocal folds are generally thicker and longer in males than in females and vibrate more slowly, hence, men usually have a lower range of pitch than women.
8. NOTE: the pharynx, mouth, nasal cavity and paranasal sinuses all act as resonating chambers that give the voice its human and individual characteristics and quality.
9. By constricting and relaxing the pharyngeal wall musculature, we produce the VOWEL sounds.
10. Facial, tongue and lip muscles help us ENUNCIATE the words

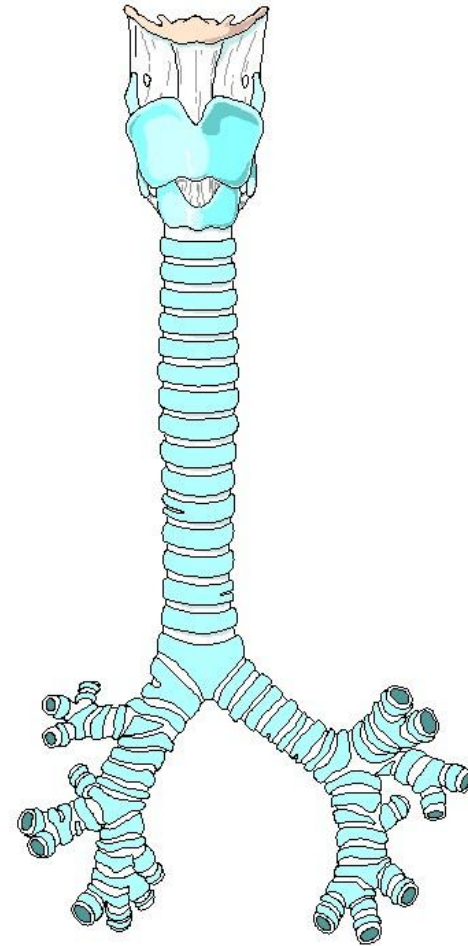
Trachea



- aka windpipe: about 12 cm long and 2.5 cm in diameter. Located anterior to the esophagus and extends from larynx to T₅ where it bifurcates into the left and right primary bronchi.
- **Trachealis muscle**: smooth muscle fibers, which, in conjunction with elastic connective tissue, attach open ends of the cartilage rings. Cartilage is “C” shaped and maintains the shape fo the trachea so it doesn’t collapse inward (upon itself) and obstruct the flow of air.
- **Carina**: the point where the trachea bifurcates into R and L bronchi; an internal ridge formed by a posterior and somewhat inferior projection of the last tracheal cartilage. Widening and distortion of the carina (via bronchoscopy) is a serious prognostic sign, since it usually indicates a carcinoma of the lymph nodes around the tracheal bifurcation.

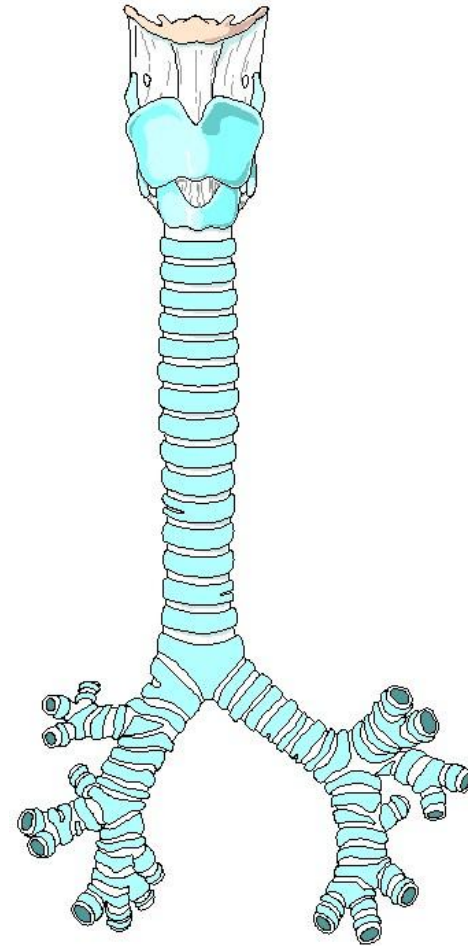
Bronchi and Bronchial Branching

- Right primary bronchus = the termination of the trachea at the sternal angle which goes into the right lung
- The right primary is more vertical, shorter and wider than the left.
- Due to these characteristics, foreign objects are far more likely to become lodged here than in the left



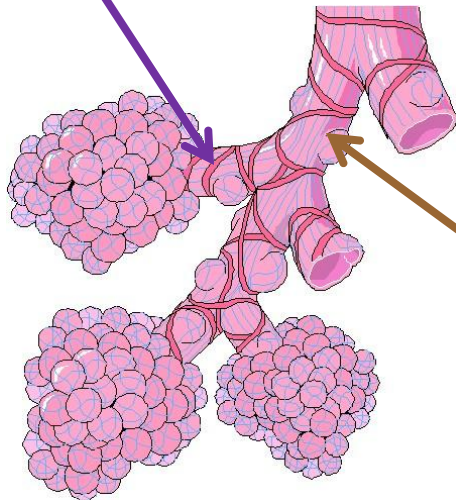
Bronchi and Bronchial Branching

- Left primary bronchus = the termination of the trachea at the sternal angle which goes into the left lung
- The left primary is longer, smaller in diameter and less vertical than the right.
- Due to these characteristics, foreign objects are much less likely to become lodged here than in the right

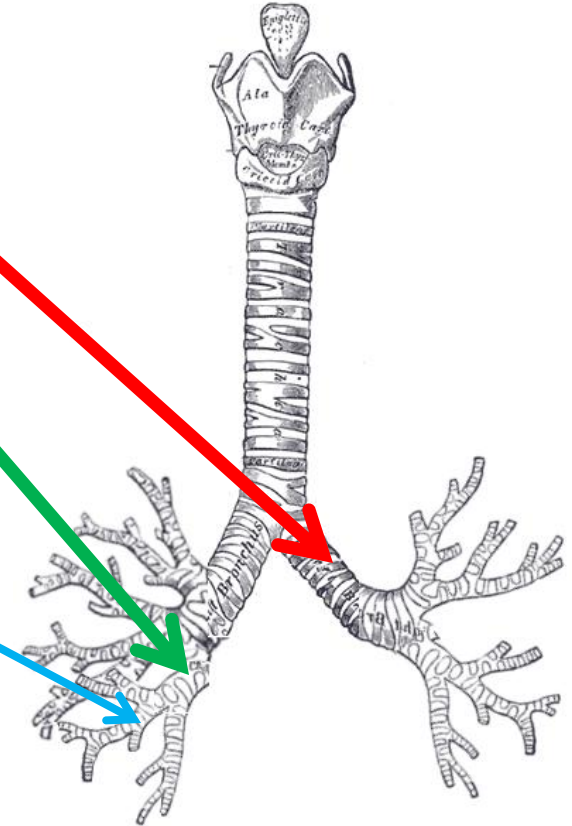


Bronchi and Bronchial Branching

- Respiratory bronchioles = smaller tubes branching off from the terminal bronchioles ending in the alveoli



- Bronchial tree = the continuous branching resembles a tree trunk, and is so named
- Secondary bronchi = division of the primary bronchi on entering the lungs: one for each lobe of the lungs (3 for the right; 2 for the left)
- Tertiary bronchi = branches of the secondary bronchi
- Bronchioles = branches of the tertiary bronchi
- Terminal bronchioles = smaller tubes branching off from the bronchioles

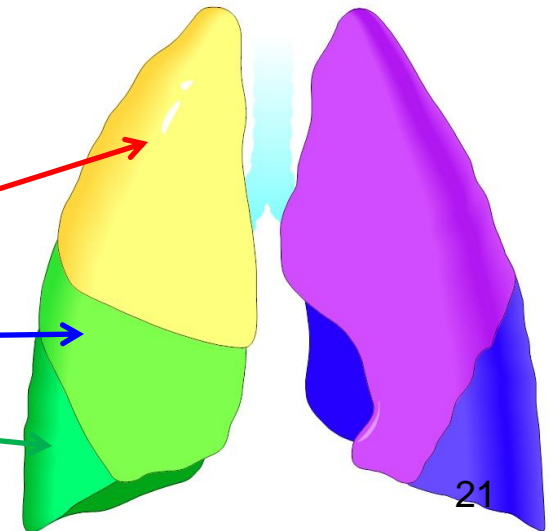
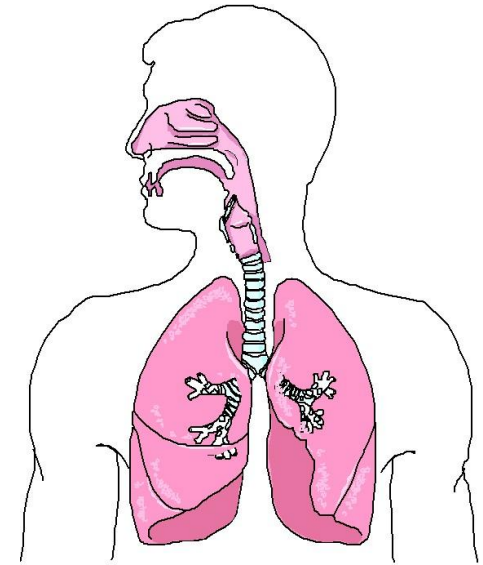


Lungs

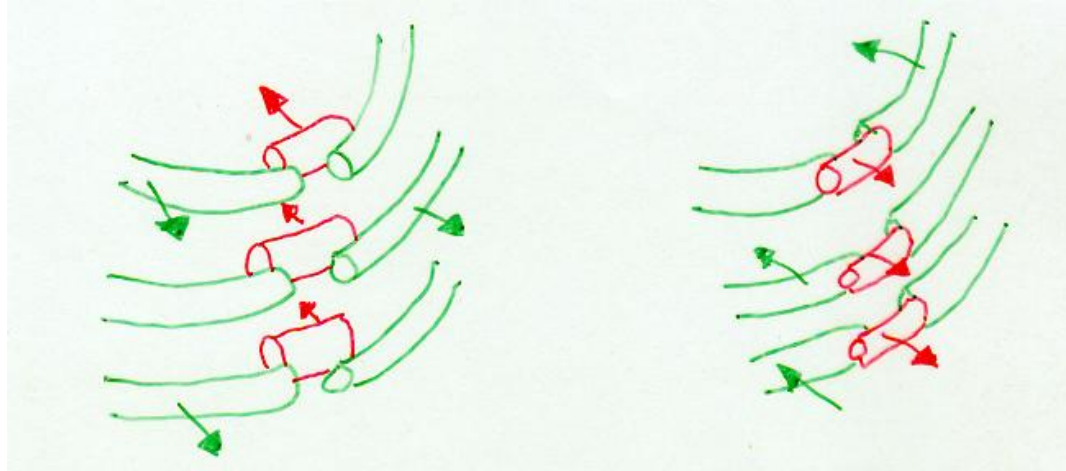
- Are paired, cone-shaped organs lying in the thoracic cavity – separated from each other by the heart and other mediastinal structures
- Pleural membranes – are 2 layers of serous mesothelium which enclose and protect each lung
- Parietal pleura = the outer layer of the pleural membrane which is attached to the wall of the thoracic cavity
- Visceral pleura = inner layer of the pleural membranes which is attached to the lungs themselves
- Pleural cavity = a small potential space between the pleura which contains lubricating fluids secreted by the membranes. This fluid prevents friction between the membranes and allows them to move easily on one another during breathing.

Lungs

- **Base** = broad inferior portion of the lung; concave and fits over the convex area of the diaphragm
- **Apex (cupula)** = the narrow superior portion of the lung
- **Costal surface** = the surface of the lung resting against the ribs; is rounded to match the curvature of the ribs
- **Mediastinal surface** = contains the hilus, through which bronchi, pulmonary vessels, lymphatics and nerves enter and exit. These are held together by the pleura and connective tissue and constitute the **ROOT** of the lung
- **Cardiac notch** = medial cavity on the surface of the left lung which fits around the heart.
- **Lung size** = right lung is thicker and broader than the left. It is shorter than the left lung because the diaphragm is higher on the right to accommodate the liver lying below it.
- **Right lung has 3 lobes: Superior, Middle and Inferior**
- **Left lung has 2 lobes: Superior and Inferior**



Pulmonary Pathology – Flail Chest

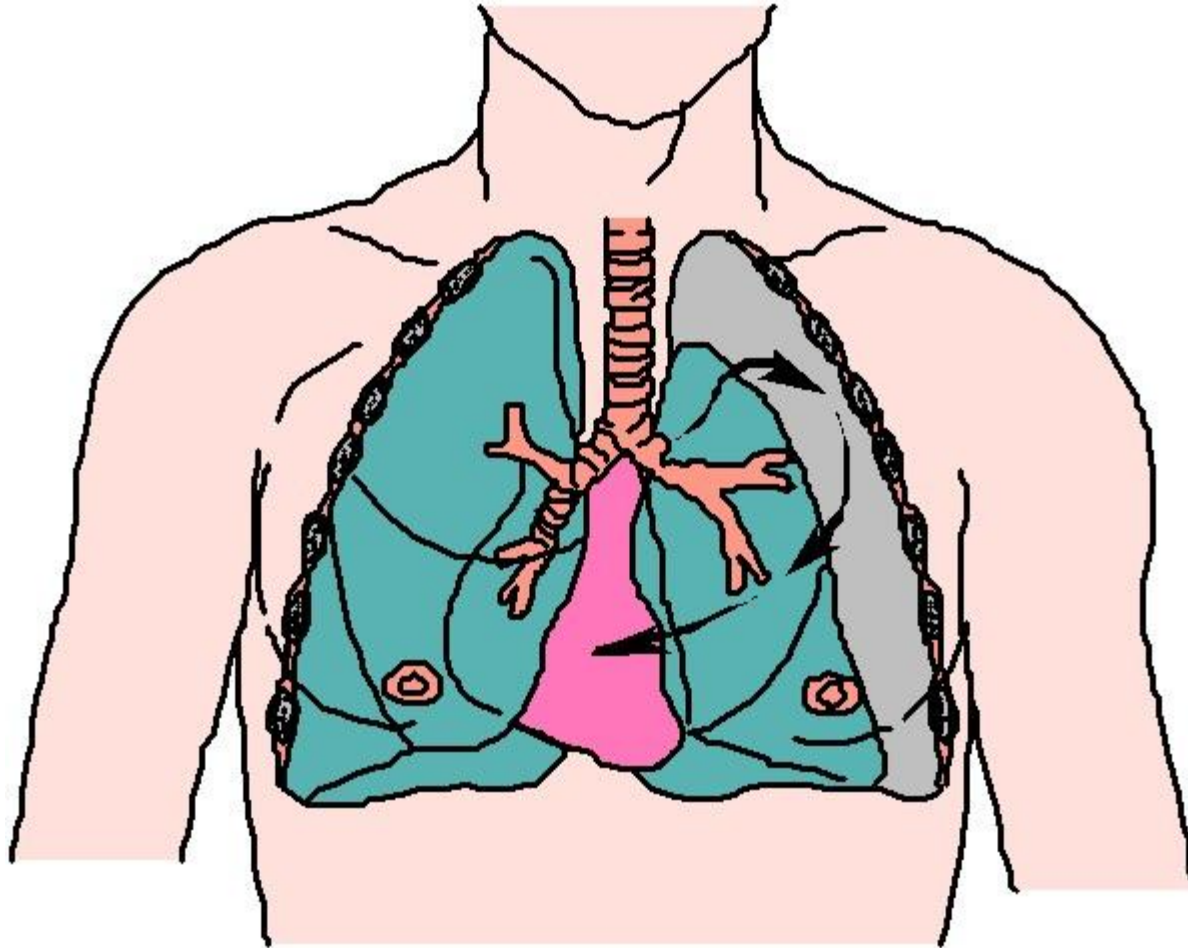


LEFT	RIGHT
<ol style="list-style-type: none"><li data-bbox="146 861 537 911">1. Inhalation<li data-bbox="146 953 788 1089">2. Undamaged chest expands<li data-bbox="146 1118 759 1253">3. Damaged section collapses IN	<ol style="list-style-type: none"><li data-bbox="967 861 1377 911">1. Exhalation<li data-bbox="967 953 1609 1089">2. Undamaged chest contracts<li data-bbox="967 1118 1792 1253">3. Damaged section moves OUT
<p data-bbox="401 1289 1561 1346">“Steering Wheel in the Chest Syndrome”</p>	

Pulmonary Pathology – Flail Chest

- May be accompanied by pneumothorax and/or hemothorax
 - Pneumothorax = air in thoracic cavity
 - Hemothorax = blood in thoracic cavity
 - Chylothorax = chyle in the thoracic cavity
 - Empyema = pus or necrotic tissue within the pleural space and/or thoracic cavity
 - Transudate = low protein fluid that has leaked from normal blood vessels
 - Exudate = protein-rich fluid that has leaked from blood vessels with increased permeability

Pneumothorax



Transudate Characteristics

Characteristic	Transudate	Associated with
Appearance	Clear	<ol style="list-style-type: none"> 1. ↑ Negative pressure within pleural cavity 2. Ascites 3. Hypertension 4. CHF 5. Nephritis 6. Hepatic cirrhosis
Sp. G.	< 1.016	
Clot	Absent	
Protein	< 3 g/dl	
WBC's	Few lymph's	
RBC's	Few	
Glucose	= serum levels	
LDH	Low	

Exudate Characteristics

Characteristic	Exudate	Associated with
Appearance	Cloudy, turbid	<ol style="list-style-type: none"> 1. Infections 2. Pulmonary infarctions 3. Neoplasms 4. Pleurisy due to RA
Sp. G.	> 1.016	
Clot	Present	
Protein	> 3 g/dl	
WBC's	Many; may be purulent	
RBC's	Variable	
Glucose	Slightly less than serum levels	
LDH	High	

Empyema Associated with:

- Pneumonia
- Pulmonary abscess
- Esophageal perforation
- Perforation due to mediastinitis
- Tuberculosis
- Fungal or viral disease

Clinically Relevant Respiratory Volumes -- 1

Abbreviation	Name	Definition	Volume
IRV	Inspiratory Reserve Volume	Very deep breath	3100 mL
TV	Tidal Volume	Normal breath	500 mL
IC	Inspiratory Capacity	IRV + TV; total inspiratory capacity of the lungs	3600 mL
ERV	Expiratory Reserve Volume	Normal inhalation with FORCED expiration	1700 mL
VC	Vital Capacity	IRV + TV + ERV; vigorous and complete exhalation after a very deep breath	5300 mL
RV	Residual Volume	Air remaining in lungs after ERV; air left in lungs after maximal exhalation	1200 mL

Clinically Relevant Respiratory Volumes – 2 – Derived Volumes

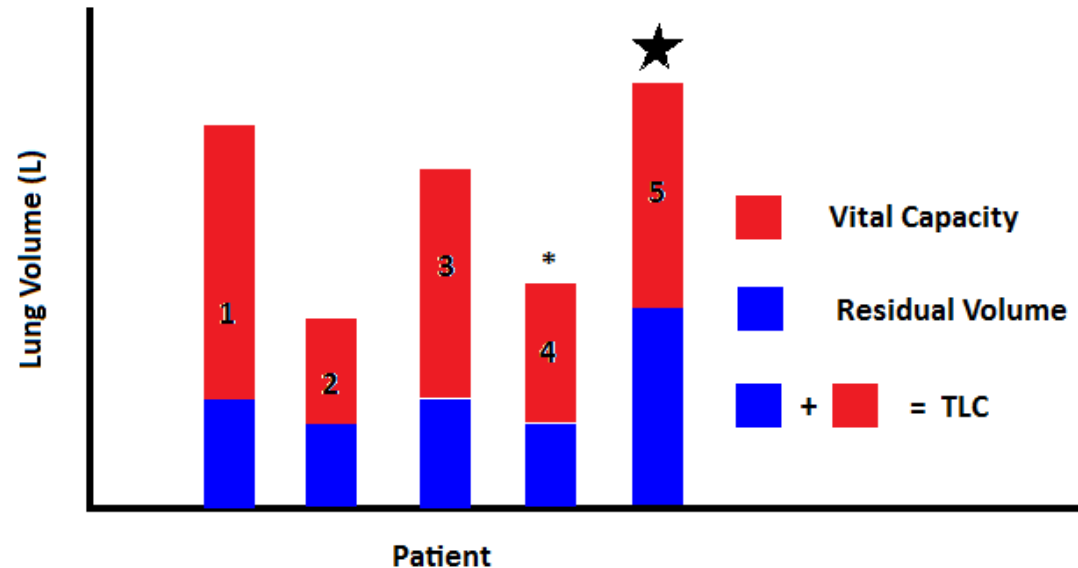
FVC	Forced Vital Capacity	Total volume of air exhaled from the lungs
FEV ₁	Forced Expiratory Volume at one second	Volume of air exhaled in one second
FEV ₃	Forced Expiratory Volume at three seconds	Volume of air exhaled in three seconds

Tidal Volume (TV) Expanded

- TV = about 500 mL
- 350 mL of that is in the alveoli
- 150 mL is in airspaces in nose, pharynx, larynx, trachea, bronchioles = anatomic dead space
- Another “Derived Volume” is the Minute Volume of Respiration (MVR)

$$\text{MVR} = \text{TV} * \text{RR}$$

Lung Volumes



1. Male – 6’3”, late teens – Normal
 2. Female – 4’11”, Heptagenarian – Normal
 3. Male – 5’10”, 40 YOA – Normal
 4. Male – 5’10”, 40 YOA, Interstitial Pulmonary Fibrosis
 5. Male – 5’10”, 40 YOA, Bronchitis with Emphysema
- NOTE: #1 and #2 are normal for their age, gender, height
 - NOTE: #3, #4 and #5 are standardized to 40 YOA
 - NOTE: #4: ↓ TLC due to restrictive nature of the disease
 - NOTE: #5: ↑ TLC due to increased RV; increased RV is due to air trapping

Minimal Volume = MV

- When the atmospheric pressure equals the intra-pleural pressure, some of the RV is forced out. What is left is the MV
- VERY USEFUL
- Fetal lung that's never breathed won't float in water
- Baby lung that has inhaled air WILL
- Therefore, stillborn baby lung SINKS in water
- And lung from baby killed after birth FLOATS in water

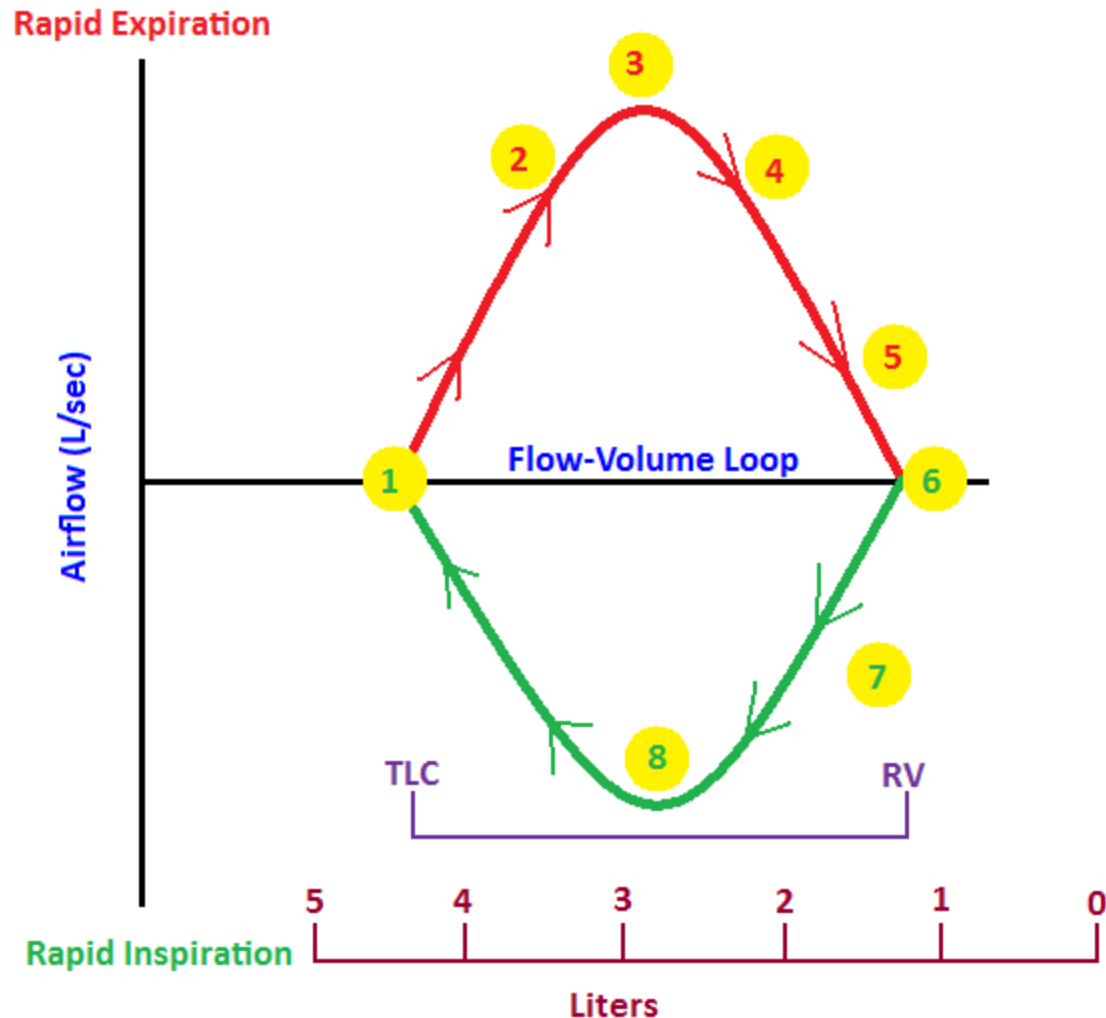
Mammalian Diving Reflex

1. Blood diverted from extremities and localizes to heart, lungs and brain
2. Metabolism to lungs and heart decreases
3. Decreases oxygen requirements
4. Has three (3) requirements:
 1. TEMP: water temp must be $\leq 70^{\circ}\text{F}$; the colder the water, the greater the reflex
 2. AGE: younger victims do better
 3. FACE: face MUST be in the water to stimulate the vagus (X) nerve (SUDDENLY immersed!)
5. Not all drownings are fatal! Even after 38 minutes in the water!



Flow Volume Loops – “Normal”

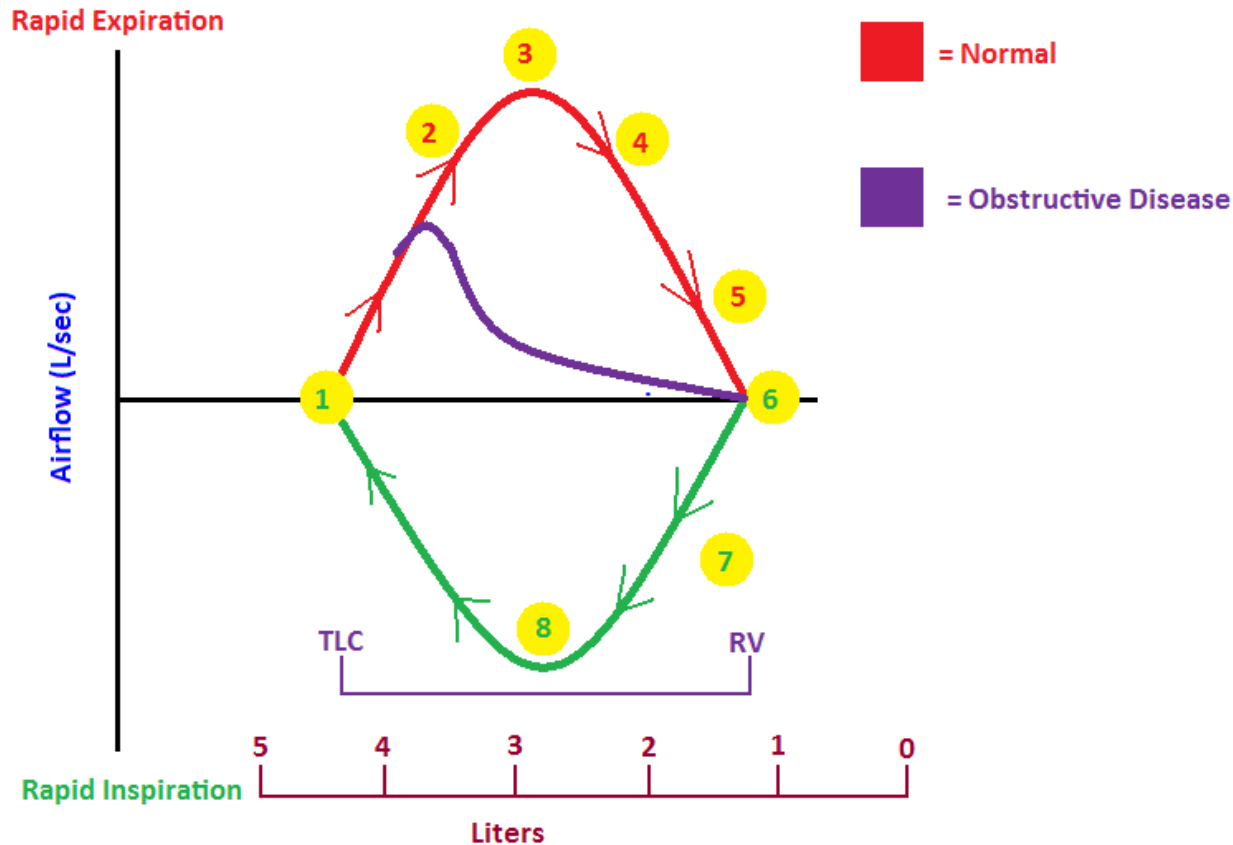
1. TLC at maximal inspiration ; relative volumes, i.e., not absolute volumes.
2. ~0.5 seconds
3. Peak EXPIRATION
4. ~1.0 seconds
 1. Reduced air flow secondary to reduced lung volume; narrowed airways reduces resistance
5. ~3.0 seconds
6. RV at maximal expiration
7. Widened bronchi; increases until peak inspiration
8. Peak inspiration



Obstructive Lung Disease

- Increased resistance, or obstruction, to/of airflow in upper or lower airways
- Obstructive flow: can't breathe OUT much
- Major symptoms: Dyspnea, Easy fatigability, wheezing, productive cough
- Diagnostic Umbrella = COPD and covers asthma, chronic bronchitis and emphysema


Flow Volume Loops – Obstructive Disease



- Emphysema: peaks early due to loss of elastic recoil and, hence, collapses to cause earlier airway closure
- Bronchitis: airway closure due to increased muscle tone ; relative volumes, i.e., not absolute volumes.

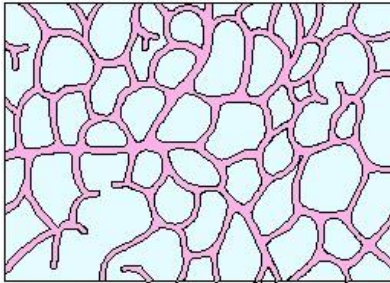
Obstructive Disease: Pursed Lip Breathing

- \uparrow resistance at mouth that causes
- \uparrow diameter of small airways that causes
- \uparrow air movement OUT of lungs that causes
- \downarrow air trapping

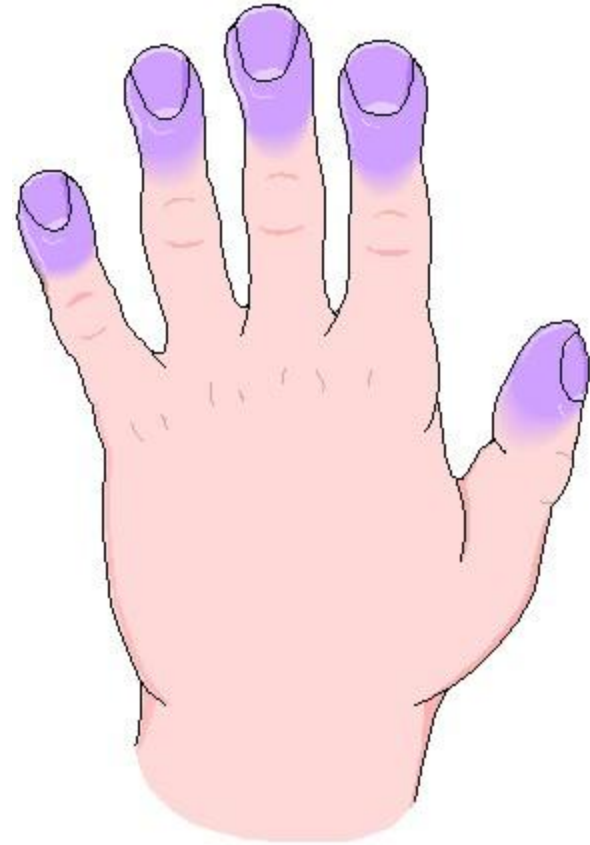
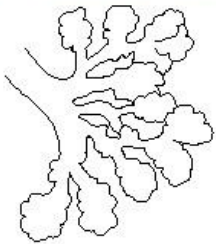
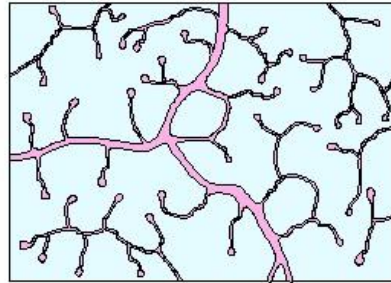


Emphysema – Alveoli and Clubbed Fingers

Normal Alveoli



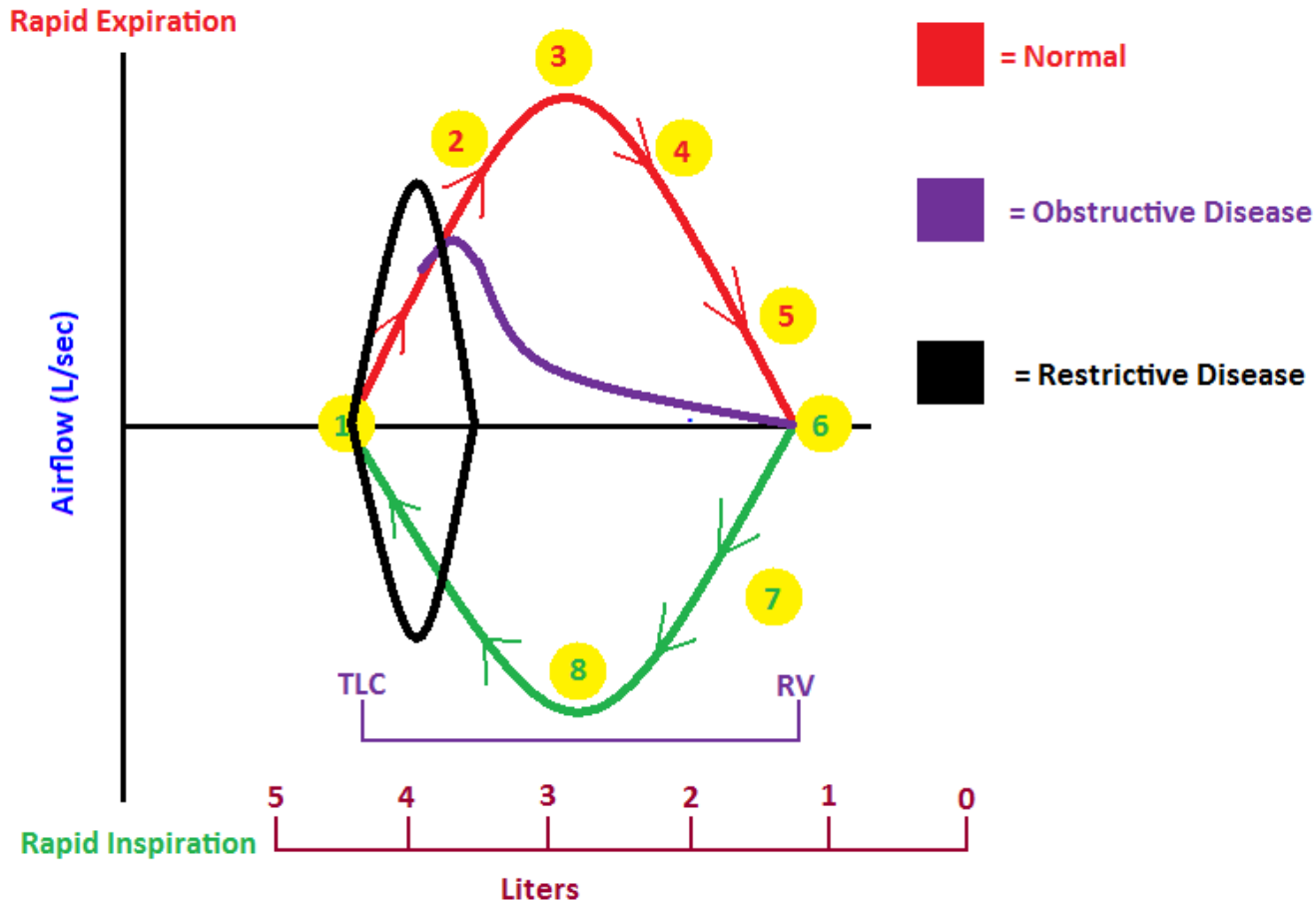
Emphysematous Alveoli



Restrictive Lung Disease

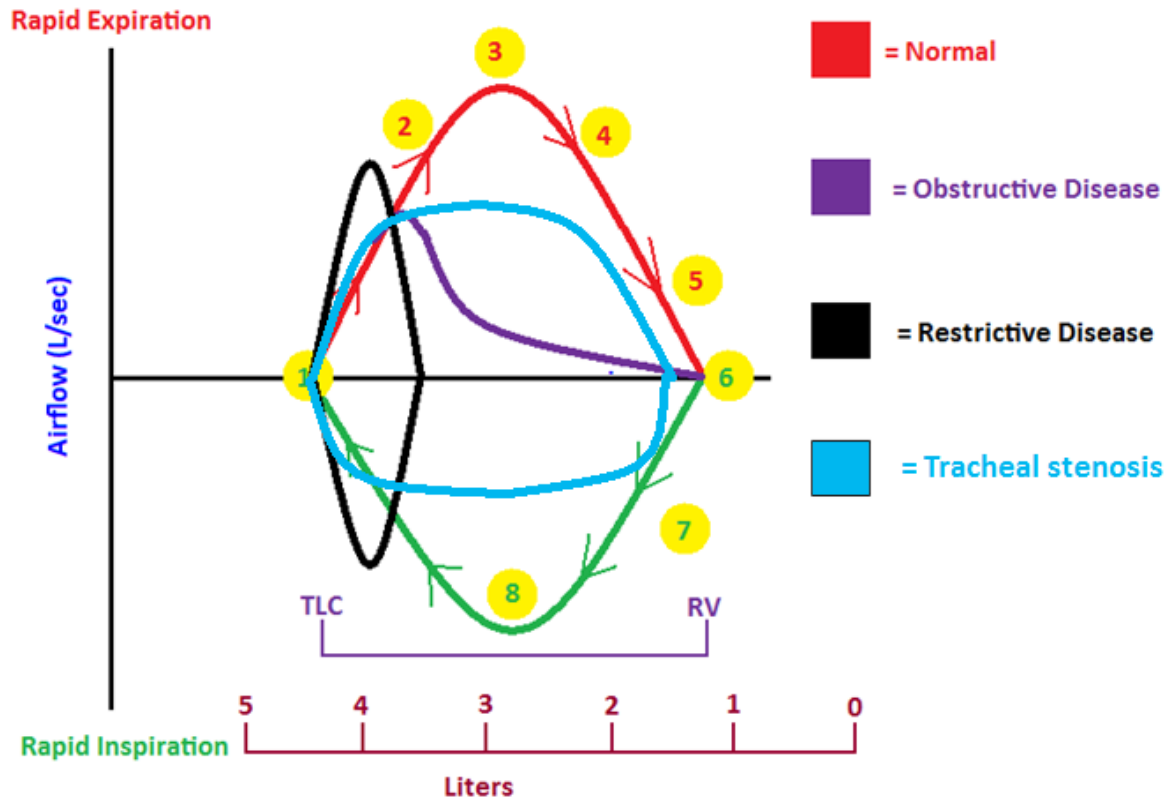
- Restricts lung expansion and sometimes prevents adequate pulmonary ventilation; due to processes that obliterate normal lung elasticity and causes lungs to get stiff.
- Restrictive flow: can't breathe IN much
- Associated with rheumatoid arthritis, bronchiolitis, silicosis, asbestosis and paraquat inhalation (herbicide from Δ^9 -THC)

Flow Volume Loops: Restrictive Disease



- Inspiration limited due to weak respiratory muscles or reduced compliance of chest wall or lungs; note maximal expiration time at 40 ~0.5 sec; relative volumes, i.e., not absolute volumes.

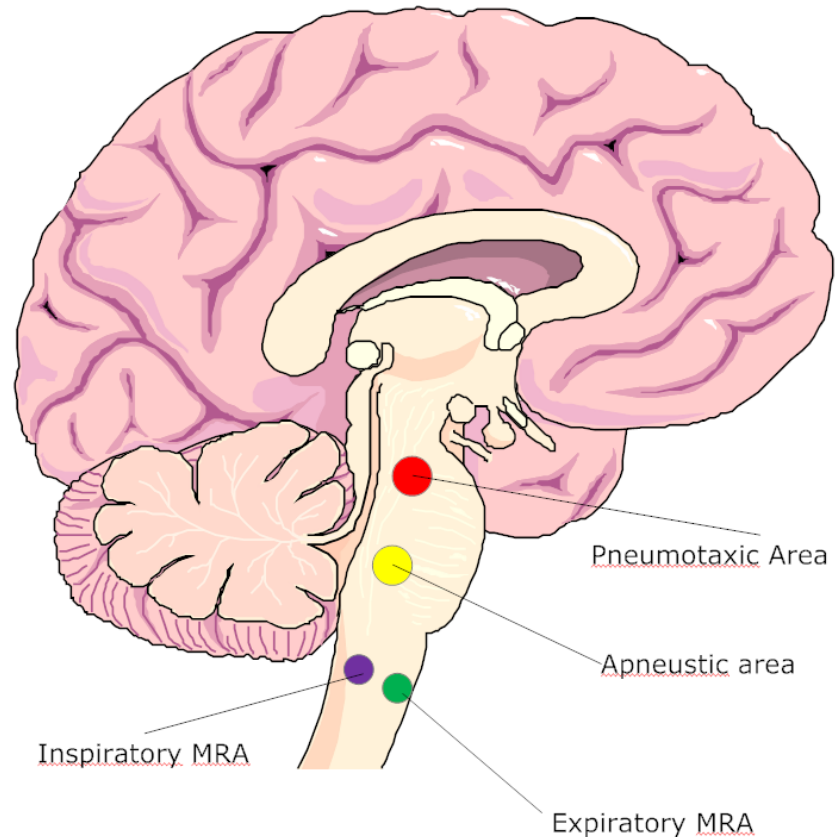
Tracheal Stenosis: Mostly Obstructive



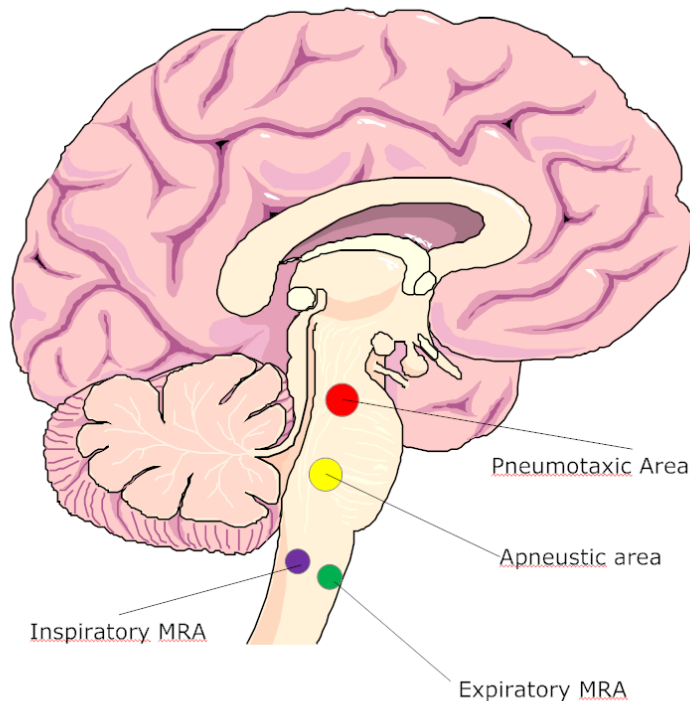
- Tracheal stenosis is a narrowing or constriction of the trachea.
- Most cases of tracheal stenosis develop when a person's trachea is injured after prolonged intubation.
- Tracheal stenosis can also develop from a number of other causes, including external injury to the throat; when a benign or malignant tumor presses on the windpipe; certain autoimmune disorders and infections. It can also develop as a side effect of radiation therapy when administered to treat a tumor in the head or neck.

Nervous Control of Respiration

- Eupnea = normal quiet breathing
- Costal breathing = shallow (chest) breathing
- Diaphragmatic breathing = deep (abdominal) breathing
- Respiratory centers = the areas from which nerve impulses are sent to respiratory muscles; located bilaterally in brainstem – include medullary rhythmicity area, pneumotaxic area and apneustic area

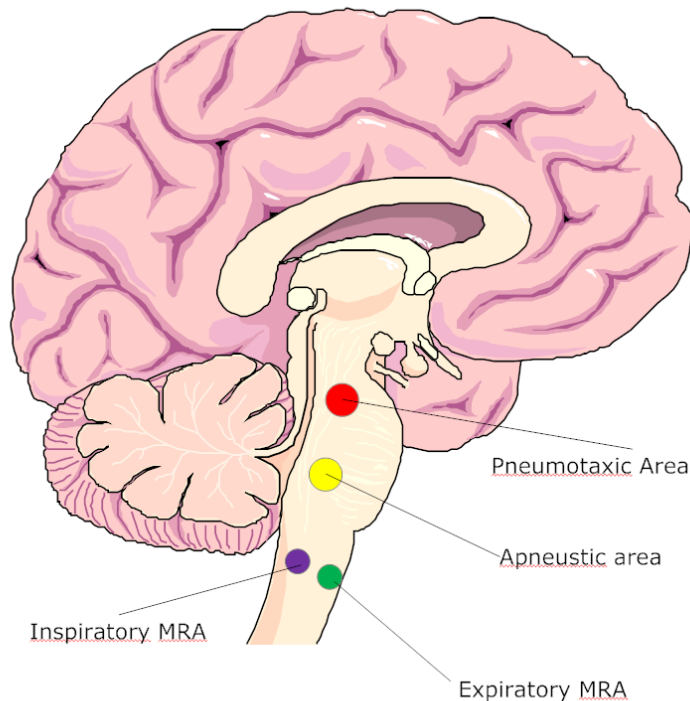


Medullary Rhythmicity Area



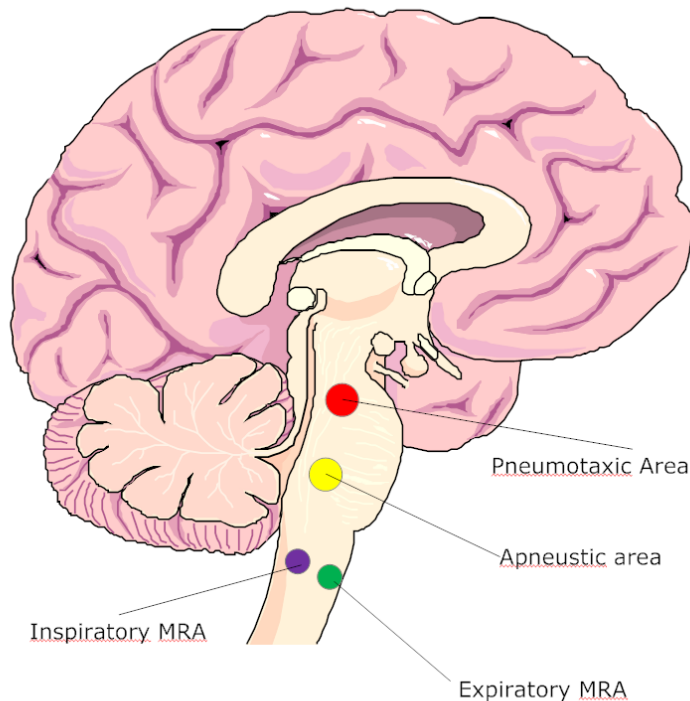
- $MRA_{(Inspiratory)}$ activated X 2 sec.
- Diaphragm and external intercostals contract.
- Inspiration occurs.
- $MRA_{(Inspiratory)}$ deactivated X 3 sec.
- Muscles relax.
- Expiration occurs.
- NORMAL quiet breathing: eupnea.

Medullary Rhythmicity Area



- $MRA_{(Inspiratory)}$ activated.
- Diaphragm, external intercostals, SCM, Pec minor, scalenes contract.
- Forced inspiration occurs.
- $MRA_{(Expiratory)}$ activated by $MRA_{(Inspiratory)}$.
- Internal intercostals and abdominal muscles contract.
- Forced expiration occurs.
- Breathing during exercising

Pneumotaxic and Apneustic Areas (Pons)



- Pneumotaxic area is **CONTINUOUSLY** inhibitory on $MRA_{(I)}$
 - Limits inspiration; therefore facilitates expiration (before the lungs get too full of air)
 - Over-rides the apneustic center
- Apneustic center prolongs inspiration; therefore inhibits expiration when the pneumotaxic area is Inactive
- Apneustic center stimulates $MRA_{(I)}$

Neurochemical Regulation of Respiration: General Respiratory Center

Both Inhibiting and Stimulating

Pain, emotional stimulus, flight, fight or freeze (tend-n-befriend)

Cerebral cortical centers (striated control of respiration)

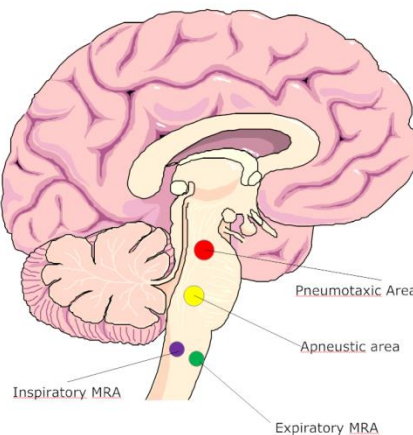
Only stimulating

Peripheral and central chemoreceptors (\downarrow pH, \uparrow pCO₂, \downarrow pO₂)

Muscle/Joint "Pump" Receptors (exercise)

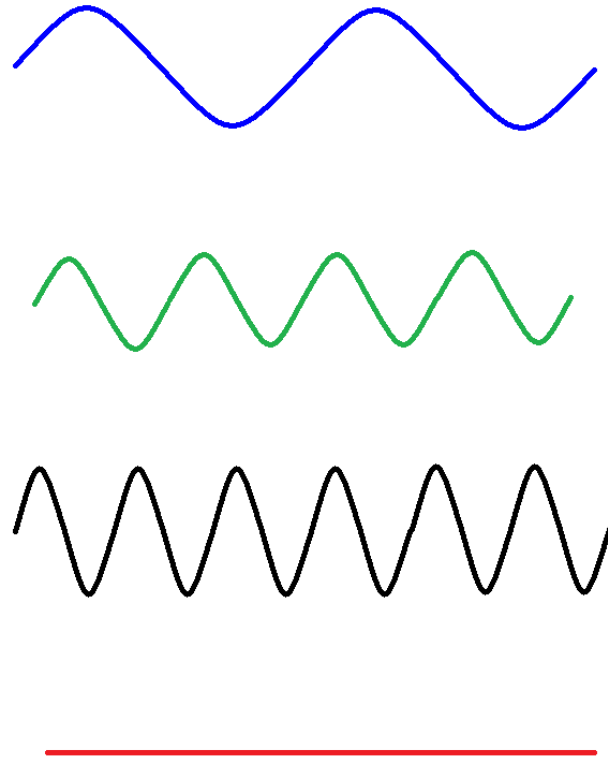
Only inhibiting

Irritant receptors (cough)
Hering-Breuer reflex



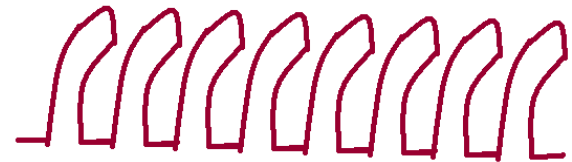
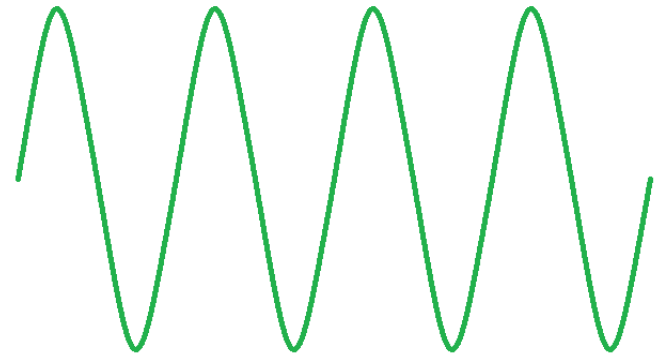
Clinically Relevant Breathing Patterns -- 1

- Bradypnea
 - Slow but regular
- Eupnea
 - Normal, quiet breathing
- Tachypnea
 - Rapid breathing;
 - Rate increases ca 4/min/°F
- Apnea
 - No breathing



Clinically Relevant Breathing Patterns -- 2

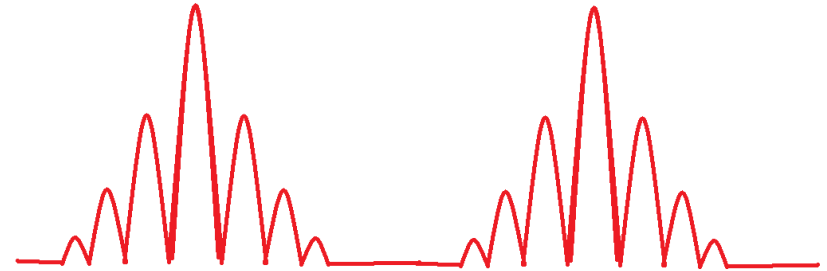- Hyperpnea
 - Deep, but normal rate
- Apneustic
 - Prolonged gasping
 - Short, inefficient respirations
 - Secondary to lesions in the respiratory centers
 - “agonal gasping”



Clinically Relevant Breathing Patterns -- 3

- **Cheyne-Stokes**

- 30-170 seconds on
- 20-60 seconds off
- Central sleep apnea syndrome, chronic heart failure, immature respiratory systems, those sleeping unaccustomed to high altitude, stroke, brain tumor, CO poisoning



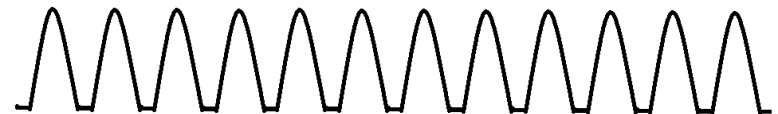- **Biot's**

- Faster and deeper with same depth
- Spinal meningitis or other CNS lesions



- **Kussmaul's**

- Faster and deeper
- Without pauses
- > 20/min; labored
- Renal failure or metabolic acidosis



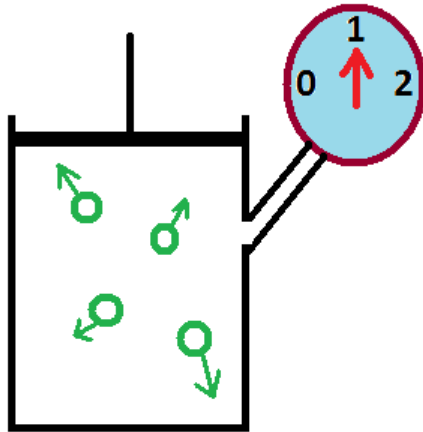
Pulmonology: Gas Laws

Boyle's Law

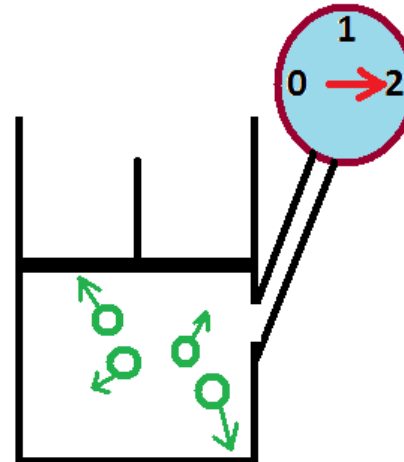
- The first gas law we'll examine is Boyle's Law.
- Boyle's Law says that the product of the pressure (P_1) and volume (V_1) of a gas under a first set of conditions is equal to the product of the pressure (P_2) and volume (V_2) it occupies under a second set of conditions:

$$P_1V_1 = P_2V_2$$

In order for Boyle's Law to work, the temperature must remain a constant.



$P_1 = 1 \text{ atm}$
 $V_1 = 1 \text{ whatever}$

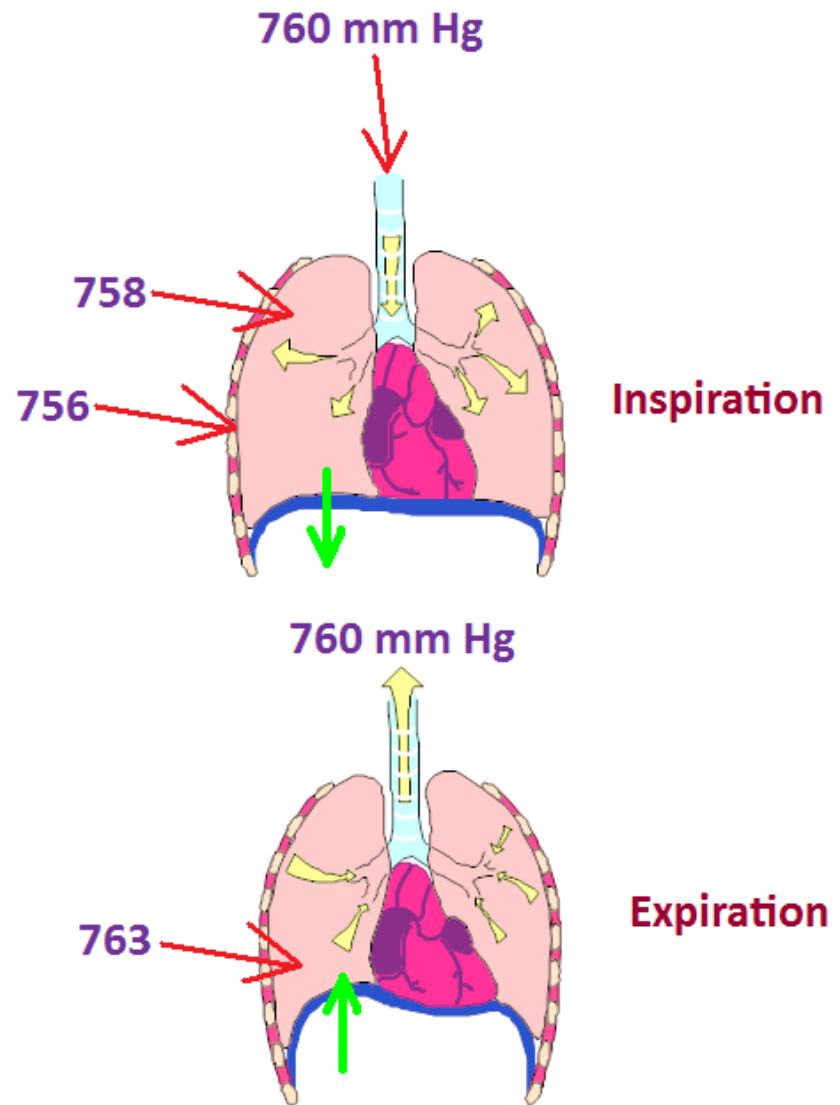


$P = 2 \text{ atm}$
 $V = 0.5 \text{ whatever}$

$$1 \times 1 = 2 \times 0.5$$

- When the pressure is increased on a gas in a cylinder fitted with a frictionless piston, the volume is proportionately reduced.
- The converse is equally as true.
- Note that if $P_1 = 1 \text{ atm}$ and $V_1 = 1 \text{ whatever}$ volume label that the product is 1.
- The same holds true for a P_2 of 2 atm and a V_2 of 0.5 whatever volume label.
- Even in this day and age of new math, 1 still equals 1.

- Boyle's Law is applicable to breathing.
- Note that just before inspiration that the atmospheric, intrapleural (in between the two membranes around the lungs) and intrapulmonic (in the lungs) pressures are all equal: 760 mm Hg.
- During inspiration, when the diaphragm contracts, the intrapleural and intrapulmonic pressures decrease (a vacuum has been created) and the air rushes in to fill the space.
- Once our lungs are full, and the diaphragm relaxes, the intrapleural and intrapulmonic pressures increase to the point to of being greater than atmospheric pressure and the air is forced out of the lungs.



Charles' Law

Charles' Law says that the volume of a gas is directly proportional to the absolute temperature of that gas while the pressure is held constant.

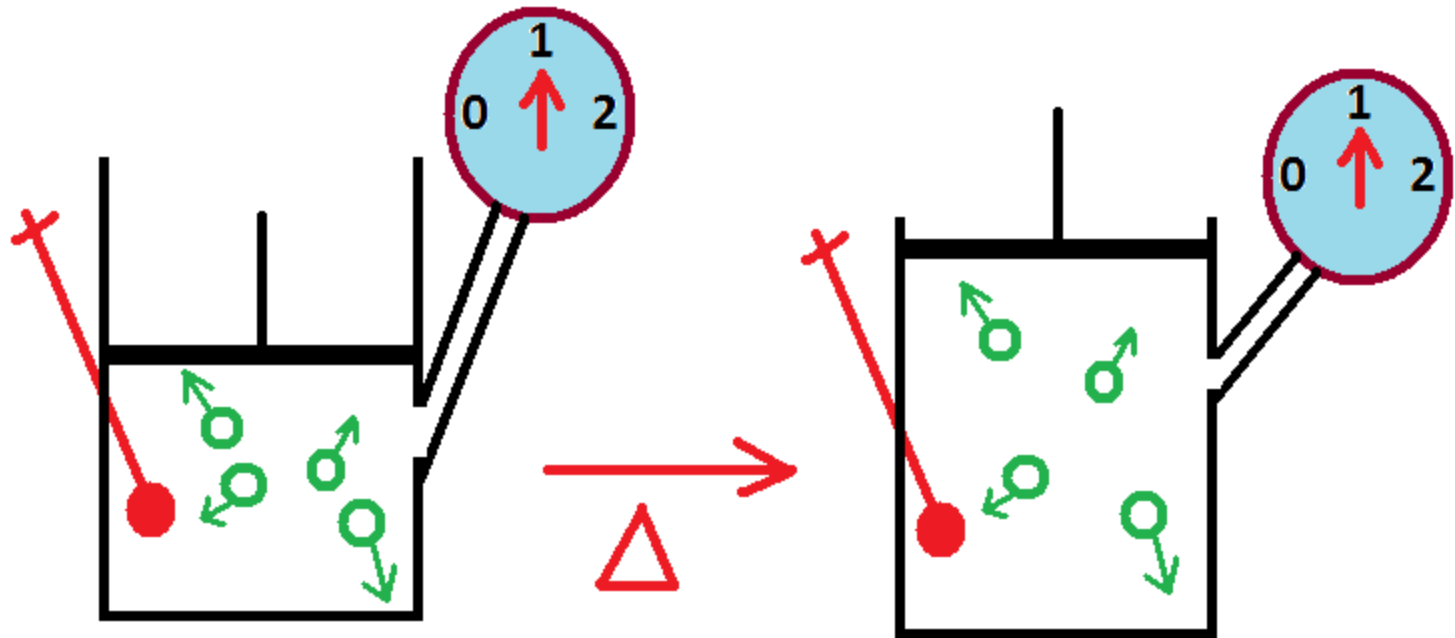
You've all seen this when you watch a hot air balloon fill with air.

Arithmetically, Charles' Law may be expressed in a manner similar to that of Boyle's Law:

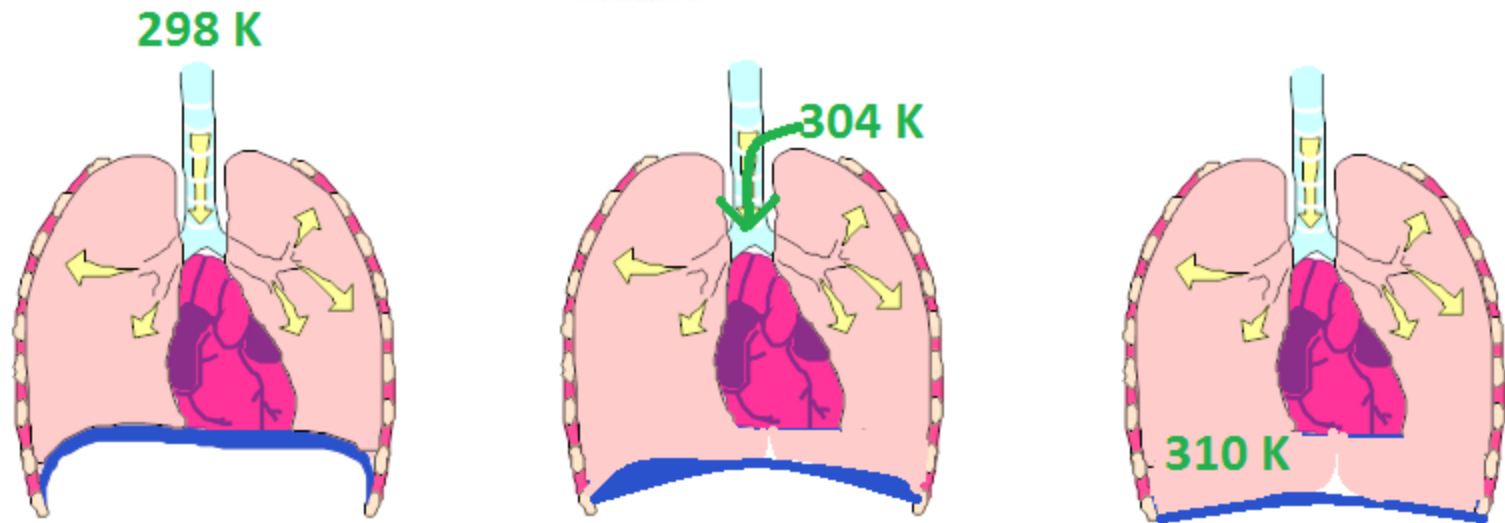
$$\frac{V_1}{T_1} = \frac{V_2}{T_2}$$

Where the first volume of a gas divided by a first absolute temperature of that gas is equal to the second volume of the gas divided by its second absolute temperature.

- Note that the pressure never changes when a gas in a cylinder kept at constant pressure is heated and its volume expands.



- Charles' Law also is applicable to breathing.
- Given that the temperature of the air outside the body is generally cooler than the air inside the body, this pretty much makes sense,
- i.e., as we inhale cooler air, when it heats up, it takes up more space causing our lungs to fill with the heated air and increase their volumes from completely exhaled to completely inspired.



Gay-Lussac's Law

- If volume is held to a constant,
- Then pressure and absolute temperature vary directly

$$\frac{P_1}{T_1} = \frac{P_2}{T_2}$$

The Combined Gas Law

The combined gas law is just that: combined.
It is Boyle's, Charles' and Gay-Lussac's Laws combined:

$$\frac{P_1V_1}{T_1} = \frac{P_2V_2}{T_2}$$

Remember, too, that the temperature
MUST be the absolute temperature.
Note the Boyle's part and the Charles' part
and the Gay-Lussac's part of this law.

Dalton's Law

- Dalton's Law is defined as "the pressure of a mixture of gases is equal to the sum of the pressure of each individual gas (partial pressure)", i.e., $P_T = P_1 + P_2 + P_3 + P_4 + \dots + P_n$,
 - where P_T is the total pressure of the gaseous mixture,
 - P_1 is the partial pressure of gas 1,
 - P_2 is the partial pressure of gas 2,
 - P_3 is the partial pressure of gas 3, ad nauseum.

Dalton's Law

- Each gas in a mixture of gases exerts its own pressure, as if all the other gases were not present. These individual pressures exerted by the gases are called “partial pressure”, “ p ”, which makes up the final total pressure of the gas mixture.

Dalton's Law -- Example

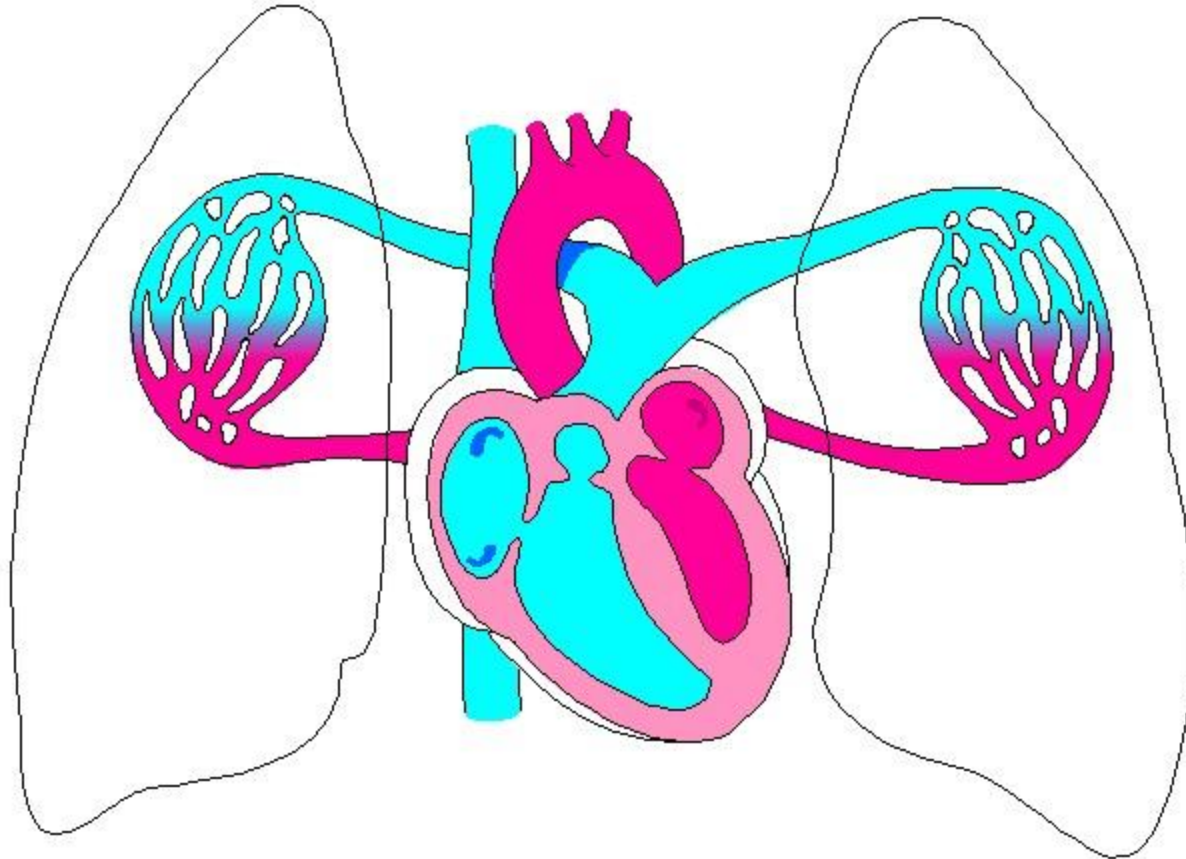
Component	Per cent (%) Composition	pGas (mm Hg)
Nitrogen	78	592.8
Oxygen	21	159.6
Argon	0.93	7.068
Carbon dioxide	0.03	0.228
Others	0.04	0.304
Total	100	760

Henry's Law

- Says that the greater the pressure of a gas over a liquid, the greater the solubility of that gas in the liquid.
- Example: sody pop
- Example: bends – nitrogen bubbles

Gas	Solubility Coefficient
CO ₂	0.57
O ₂	0.024
N ₂	0.012
He	0.005±

SHOCK!!!!



Types of Shock

1. Hemorrhagic (blood loss)
2. Respiratory (inadequate oxygen supply)
3. Neurogenic (loss of vascular control by the nervous system)
4. Psychogenic (fainting)
5. Cardiogenic (inadequate heart functioning)
6. Septic (severe infection)
7. Anaphylactic (allergic reaction)
8. Metabolic (loss of body fluids)

Stages of Shock: 1

- Cardiac output reduction
- Causes reduced MAP
- Reduced MAP stimulates aortic baroreceptors
- Aortic baroreceptors stimulate SNS to increase HR and contraction to increase cardiac output
- **LOOK FOR: elevated heart rate, slightly reduced BP and a barely reduced cardiac output**

Stages of Shock: 2

- SNS increases catecholamine output
- These decrease arteriolar diameter in NON-vital tissues and directs blood to the heart and brain
- **LOOK FOR: cool skin, thirst, elevated Sp.G., reduced peripheral pulses, reduced urinary output**

Stages of Shock: 3

- With continuing shock and/or further reduced compensatory mechanisms, O_2 availability/delivery to cells is reduced
- This reduction alters metabolism from aerobic to anaerobic metabolism reducing ATP levels and **INCREASING** lactate levels
- **LOOK FOR: reduced pO_2 , increased lactate, lowered body temperature, fatigue and severe muscle weakness**

Stages of Shock: 4

- As shock continues, reduced blood flow causes an increase in CO_2
- The CO_2 combines with water (via carbonic anhydrase) to make more carbonic acid which lowers the pH and increases medullary responses
- These medullary responses increase the RR and depth of ventilation to blow off the excess CO_2
- **LOOK FOR: tachypnea, hyperpnea, reduces pO_2 , reduced pH, elevated pCO_2 which drops and anxiety (if conscious)**

Stages of Shock: 5

- Elevated organic acids drive increased vasodilation which reduces venous return to the heart
- The vasodilation causes a reduced cardiac output that stimulate the SNS to cause constriction
- The vasoconstriction reduces blood flow to the cells which reduces the pO_2 and the pH
- **LOOK FOR:** hypotension, elevated pCO_2 , reduced pO_2 , reduced pH, tachycardia, condition worsening

Stages of Shock: 6

- Further reductions in pO₂ and pH with accompanying destructive enzyme release causes membrane permeability
- This increased permeability reduced ECF Na⁺ and increases ECF K⁺ with a secondary increase in ICF fluid levels
- **LOOK FOR: reduced cardiac output, WAY hypotension, bradycardia, arrhythmias, increased LDH activity, increased AST (SGOT) activity, increased CK activity and hyperkalemia**

Stages of Shock: 7

- Reduced blood flow and increased wastes cause micro-clots to form throughout the body – this uses up clotting factors
- **LOOK FOR: elevated PT, PTT; bleeding from orifices**
- DIC: pathological coagulation – DAMAGES rather than protects area – generalized bleeding occurs; associated with incomplete abortion, lung, brain and prostate surgeries = Disseminated Intravascular Coagulation

Stages of Shock: 8

- With worsening shock, ya get general organ deterioration
- If MAP goes below 60 mm Hg, get reduced blood flow to heart and brain, leaving them unprotected and without compensatory mechanisms
- **LOOK FOR:** reduced cardiac output, stupor, muffled heart sounds, arrhythmias, coma

Stages of Shock: 9

- Heart action further depressed due to the following
 - Reduced ATP
 - Elevated lactate
 - Increased bacterial toxins (GI)
 - Increased myocardial toxic factor
- Heart stops
- **LOOK FOR: cardiac arrest**